

## Hidradenitis suppurativa: A comprehensive review

Ali Alikhan,<sup>a</sup> Peter J. Lynch, MD,<sup>b</sup> and Daniel B. Eisen, MD<sup>b</sup>  
*Sacramento, California*

Hidradenitis suppurativa, also known as acne inversa, is a chronic, often debilitating disease primarily affecting the axillae, perineum, and inframammary regions. Prevalence rates of up to 4% have been estimated. Our understanding of the disease has changed over time. It is now considered a disease of follicular occlusion rather than an inflammatory or infectious process of the apocrine glands. Clinically, the disease often presents with tender subcutaneous nodules beginning around puberty. The nodules may spontaneously rupture or coalesce, forming painful, deep dermal abscesses. Eventually, fibrosis and the formation of extensive sinus tracts may result. The location of the lesions may lead to social embarrassment and the failure to seek medical treatment. Therapies in the past have consisted of long-term antibiotics, antiandrogens, and surgery. New treatments like tumor necrosis factor–alpha inhibitors have given clinicians more options against this difficult disease. (*J Am Acad Dermatol* 2009;60:539-61.)

**Learning objectives:** After completing this learning activity, participants should be able to describe the clinical presentation, demographics, and prevalence of hidradenitis suppurativa, be familiar with current controversies regarding the pathogenesis of this complex, and be able to discuss potential treatments and their outcomes.

**Key words:** acne inversa; etanercept; hidradenitis suppurativa; infliximab; Verneuil disease.

### Key points

- **HS is a chronic, recurrent, inflammatory disease presenting as painful subcutaneous nodules**
- **Double comedones, deep sinus tracts, and abscesses are characteristic for HS**
- **A diagnosis of HS is made clinically without the use of laboratory tests**

**H**idradenitis suppurativa (HS), also known as acne inversa, is a chronic, recurrent, inflammatory disease, initially presenting as tender subcutaneous nodules. These lesions may spontaneously rupture or coalesce to form deep dermal, exquisitely painful abscesses.<sup>1</sup> The abscesses have typically been described as being deep and rounded without central necrosis or pointing (though this may sometimes occur), and they often exude a purulent drainage.<sup>1,2</sup> The inflammatory abscesses ultimately heal, producing fibrosis, dermal contractures, and induration of the skin.<sup>3</sup> The disease is insidious,

### Abbreviations used:

AD:	autosomal dominant
CD:	Crohn disease
CNS:	coagulase-negative Staphylococcus
DDD:	Dowling–Degos disease
DLQI:	Dermatology Life Quality Index
FFD:	Fox–Fordyce disease
HS:	hidradenitis suppurativa
IK:	interstitial keratitis
KID:	keratitis-ichthyosis-deafness
OC:	oral contraceptive
SAPHO:	synovitis, acne, pustulosis, hyperostosis, and osteitis
SCC:	squamous cell carcinoma
TLR:	Toll-like receptor
TNF:	tumor necrosis factor

typically developing in otherwise healthy postpubertal males and females.<sup>4</sup>

Another lesion typical in HS is the double comedone, a blackhead with multiple apertures that communicate below the skin.<sup>5</sup> These abnormal comedones have been reported on flexural surfaces of children, and may be the precursors of HS lesions.<sup>6</sup> The disease process is thought to begin with occlusion of hair follicles. The occluded follicles subsequently rupture and reepithelize, resulting in sinus tracts that can house foreign material and bacteria.<sup>5</sup> Over time, these tracts can coalesce into large regions of subcutaneous honeycombing.<sup>7</sup> They can potentially dissect into deep structures including muscle, fascia, lymph nodes, the urethra, and the

From the Department of Dermatology,<sup>b</sup> University of California–Davis School of Medicine.<sup>a</sup>

Funding sources: None.

Conflicts of interest: None declared.

Reprint requests: Daniel B. Eisen, MD, University of California–Davis School of Medicine, Department of Dermatology, 3301 C St, Ste 1400, Sacramento, CA 95816. E-mail: [deisen@ucdavis.edu](mailto:deisen@ucdavis.edu).

0190-9622/\$36.00

© 2009 by the American Academy of Dermatology, Inc.

doi:10.1016/j.jaad.2008.11.911

bowels.<sup>1,2,8</sup> They release a serous to purulent malodorous discharge, resulting in both soiling of clothes and social embarrassment.<sup>9,10</sup> Ulceration of the skin has also been described with chronic HS.<sup>3</sup> The ulcers characteristically present with rolled, boggy, ragged edges and clean granulating bases.<sup>3</sup> Like most diseases, especially its analogue acne conglobata, the severity varies considerably.

Early symptoms and signs of HS are burning, pruritus, local warmth, hyperhidrosis, and pain.<sup>3,11</sup> HS may be divided into acute and chronic forms. Acute HS presents with a few deep-seated nodules, which may coalesce developing into cord-like red-to-bluish red structures.<sup>3,12</sup> Chronic HS is characterized by multiple abscesses, interconnecting sinus tracts, foul exudate from draining sinuses, inflammation in the dermis, both atrophic and hypertrophic scars, ulceration, and infection which may extend deep into the fascia.<sup>10,12</sup>

The diagnosis of HS is made clinically, and biopsies are not routinely taken.<sup>13</sup> There is no confirmatory test for HS. Criteria for diagnosis vary widely but typically include chronicity, recurrence of disease, failure to completely clear with antibiotics, characteristic multifocal lesion distribution, sinus formation, scarring and dermal contracture, presence of double comedones, multiple open comedones, nodules, papules, tenderness of lesions, and malodorous discharge.<sup>7</sup>

## DEMOGRAPHICS

### Key points

- **HS tends to begin in the second or third decades of life**
- **Females are more likely to develop HS**
- **Recent studies suggest a prevalence of about 1%**

HS typically occurs after puberty, with average age of onset in the second or third decades of life. Onset after menopause is rare.<sup>14,15</sup> Isolated case reports have described HS in prepubertal subjects, but these are associated with premature adrenarche.<sup>16-18</sup> HS prevalence may diminish over time. A recent study showed that prevalence among those 55 years of age and older was significantly lower than in younger age groups (0.5% vs 1.4%).<sup>19</sup>

A large Danish study estimated 1-year prevalence at 1.0% based on subject recollection only, and point prevalence at 4.1% based on objective findings.<sup>20</sup> The point prevalence was based on a younger adult population and may, therefore, overestimate the true prevalence of HS.<sup>7,20</sup> A recent case control study based on a representative portion of the French population (n = 10,000) estimated prevalence at

1%.<sup>19</sup> Other studies have estimated various prevalence rates ranging from 0.00033% to 4%.<sup>20-23</sup>

HS appears to be significantly more common among females. HS researchers generally accept this, but many authors have argued that certain locations appear to have sexual predilection.<sup>2,7,8,11,13,15,17,24-28</sup> Perianal HS, for instance, seems to affect males more than females.<sup>3</sup>

Some authors have suggested a higher prevalence of HS among African Americans. This has not been substantiated by any studies examining racial predilection.<sup>12,15,24,29-31</sup>

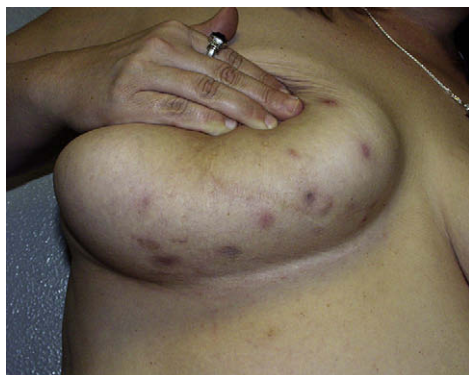## CLINICAL PRESENTATION

### Key points

- **HS most typically occurs in the axillary, inguinal, perianal, perineal, mammary, and inframammary regions**
- **The distribution pattern corresponds with the “milk line” distribution of apocrine-related mammary tissue in mammals**
- **The most commonly affected site is the axilla**
- **Perianal HS is associated with more debilitating outcomes**

HS is characterized initially by the presence of tender subcutaneous nodules. With time, the nodules may rupture, resulting in painful, deep dermal abscesses.<sup>1</sup> The lesions may be rounded, but, unlike furuncles, do not usually exhibit pointing. After rupture, the lesions often extrude a purulent, foul-smelling discharge.<sup>1,2</sup> As the disease process continues, fibrosis, dermal contractures, and induration of the skin occur. The presence of double comedones is typical of the disease. HS develops gradually in postpubertal males and females who are otherwise healthy.<sup>13</sup>

HS lesions occur most frequently in the intertriginous apocrine gland-bearing areas of the axillary, inguinal, perianal, perineal, mammary, inframammary, buttock, pubic, chest, scalp, retroauricular, and eyelid areas.<sup>1,5</sup> This distribution pattern corresponds for the most part with the “milk line” distribution of apocrine-related mammary tissue in mammals. The sites affected in HS correspond not only to the location of apocrine glands in the body but also to that of terminal hair follicles dependent on low androgen concentrations.<sup>32</sup> One study with 388 HS patients demonstrated axillary involvement in 278 patients (72%), perianal involvement in 125 patients (32%), groin involvement in 92 patients (24%), and mammary involvement in 32 patients (8%).<sup>33,34</sup> Similar rates were seen in a study by Barth et al.<sup>35</sup> Perineal HS is associated with a much higher rate of recurrence (74% in one study) and more



**Fig 1.** Inflammatory papules and nodules in the inframammary area typical of hidradenitis suppurativa. (Courtesy of Michael S. Wong, MD, Department of Plastic Surgery, University of California—Davis, Sacramento, CA.)

debilitating outcomes than axillary HS.<sup>15,24</sup> Lesions often initially occur in the axillae and anogenital regions, but once the disease advances, new lesions develop in areas of friction, including the submammary region (Fig 1), the nape of the neck, the waistband area, and the inner thighs.<sup>2</sup>

Patients with anogenital HS may also have disease in the anal canal (30 of 132 patients in one study).<sup>26</sup> HS in the anal canal lies superficial to the internal sphincter and begins in the lower two-thirds of the canal, distal to the dentate line (the transition zone from columnar epithelium to squamous epithelium).<sup>26</sup> This corresponds with the distribution of apocrine glands and hair follicles in the anal canal.<sup>26</sup> If lesions are seen proximal to this area, disorders such as Crohn disease (CD) or a fistulous abscess should be considered.<sup>26</sup>

## CLINICAL STAGING

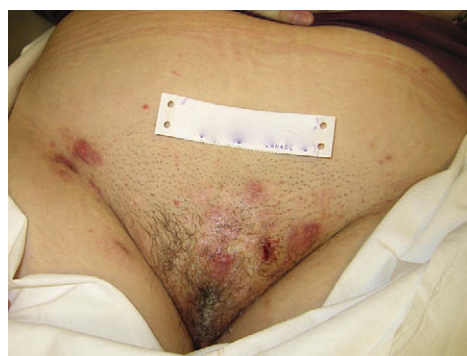### Key points

- Hurley's staging system is simple and relies on the subjective extent of diseased tissue
- The Sartorius system is more sophisticated than Hurley's and is likely to supplant it as a means for conducting clinical trials

One of the first staging systems for HS was proposed by Hurley (Table I).<sup>36</sup> Hurley separated patients into three groups based largely on the presence and extent of cicatrization and sinuses (Figs 2, 3, and 4).<sup>36</sup> It has been used as a basis for clinical trials in the past and is a useful basis to approach therapy for patients.<sup>37</sup> Its advantage is its simplicity. However, Sartorius et al<sup>38</sup> have suggested that the Hurley system is not sophisticated enough to assess treatment effects in clinical studies. They suggest a system that incorporates the involved anatomic regions, number and types of lesions,

**Table I.** Hurley staging system for hidradenitis suppurativa

Hurley stage	Extent of disease in tissue
I	Abscess formation (single or multiple) without sinus tracts and cicatrization
II	One or more widely separated recurrent abscesses with tract formation and scars
III	Multiple interconnected tracts and abscesses throughout an entire area



**Fig 2.** Hurley stage I—single or multiple abscesses without cicatrization and sinus tracts.

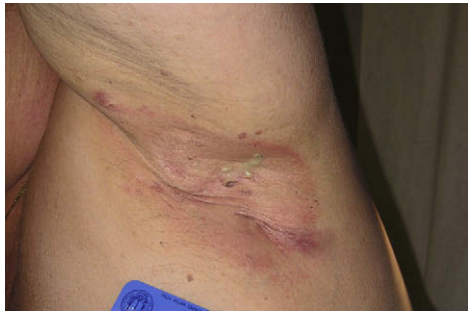distance between lesions, and the presence of normal skin in between lesions.<sup>38</sup> Points are accumulated in each of the mentioned categories and added to give both a regional and total score. In addition, the authors suggest adding a visual analog scale for pain or using the dermatology life quality index (DLQI) when assessing HS.<sup>38</sup> This system will likely be the basis of many future clinical trials.

## DIFFERENTIAL DIAGNOSIS

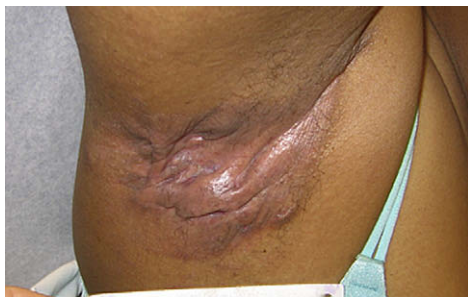### Key points

- The differential diagnosis for HS is extensive, but can easily be differentiated from other diseases by the age of onset and characteristic locations of the lesions

The differential diagnosis for HS is extensive (Table II) but is usually easy to discern from other diseases.<sup>3,39</sup> HS can be differentiated from other diseases by the appearance of the lesions, postpubertal age of onset, characteristic locations, resistance to antibiotics, recovery of multiple species (rather than a single species) of bacteria on culture, absence of fever, and the lack of significant laboratory findings (Fig 5). An important feature distinguishing almost all of these other diseases from HS is the specific histology (often with special stains for organisms) in the non-HS diseases.



**Fig 3.** Hurley stage II—one or more widely separated recurrent abscesses, with tract formation and scars.



**Fig 4.** Hurley stage III—multiple interconnected tracts and abscesses throughout an entire area.

## ETIOPATHOGENESIS

### Key points

- Long thought to be a disorder of apocrine origin, it is now thought to be caused by follicular occlusion
- Families with autosomal dominance type inheritance have been reported
- Hyperandrogenism likely does not play a role in HS
- Bacteria are probably secondary colonizers, which may exacerbate HS, but they are not the primary etiologic agents
- Poor hygiene does not cause HS
- Some investigators postulate that there may be an underlying immunologic aberration involved in the pathogenesis of HS; more work needs to be done in this field before any conclusions can be made
- Smoking and obesity are not primary causes of HS but are strongly associated with the disease and may exacerbate it

### Follicular and glandular factors

**Early studies implicating apocrine glands.** Our understanding of the pathogenesis of HS has changed over time. It was originally described by the French physician, Velpeau, in 1839, as indicated by Slade et al.<sup>1</sup>

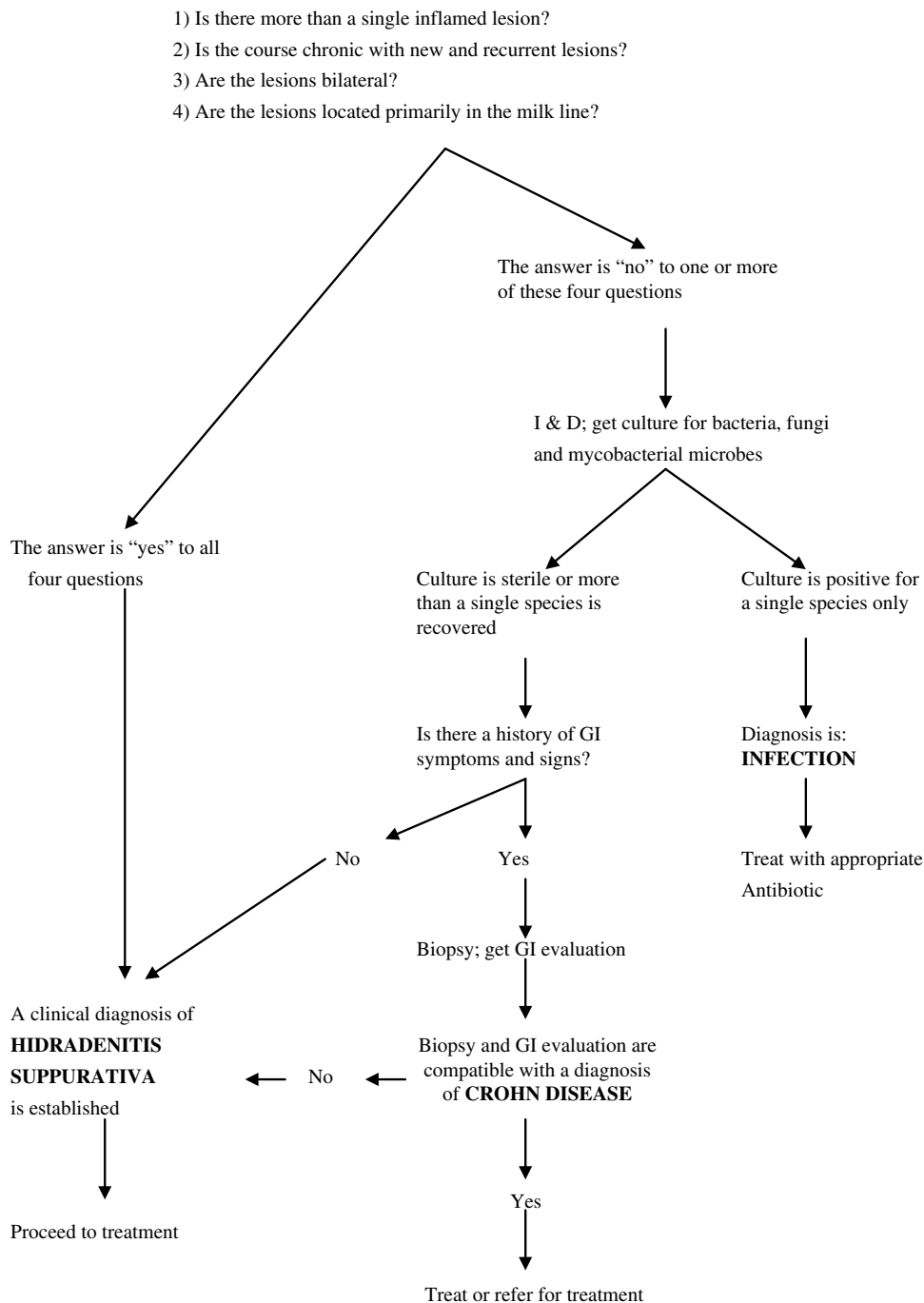
**Table II.** Differential diagnosis of hidradenitis suppurativa

Early lesions	Late lesions
Acne	Actinomycosis
Carbuncles	Anal fistula
Cellulitis	Cat scratch disease
Cutaneous blastomycosis	Crohn disease
Dermoid cyst	Granuloma inguinale
Erysipelas	Ischiorectal abscess
Furuncles	Lymphogranuloma venereum
Inflamed epidermoid cysts	Nocardia infection
Lymphadenopathy	Noduloulcerative syphilis
Perirectal abscess	Pilonidal disease
Pilonidal cyst	Tuberculous abscess
	Tularemia

He wrote about a patient with circumscribed inflammation with superficial abscesses affecting the skin of the axilla, mammary, and perianal areas.<sup>1</sup> In 1854, Verneuil reported on a series of patients with similar lesions in the axilla and groin, and hypothesized that the primary cause was purulent inflammation of the sweat glands.<sup>1,30</sup> He named the disease HS. This became the accepted theory for more than a century. In 1922, Schiefferdecker<sup>40</sup> classified sweat glands as eccrine and apocrine. In 1939, Brunsting,<sup>11</sup> who completed a study using histologic specimens from 16 patients, suggested that the apocrine gland was to blame for the disease.<sup>11</sup> He suggested that the earliest cellular reaction seen in HS was an inflammatory reaction in the subcutis, localized to the lumen of the apocrine gland and neighboring periglandular connective tissue. He stated that these findings supported an earlier opinion that the disease starts with an infectious process that enters the hair follicle and excretory tubule of the apocrine glands, but does not cause inflammation until the gland itself is reached.<sup>11</sup> The infection then was theorized to spread in the subcutis by way of lymph channels.<sup>11</sup>

In 1955, Shelley and Cahn<sup>41</sup> attempted to simulate HS by applying belladonna adhesive tape continuously for 2 weeks to manually depilated axillary skin.<sup>41</sup> Three of the 12 study subjects developed deep, tender nodules similar to HS lesions.<sup>41</sup> Histologically, keratinous plugging of the apocrine sweat duct, dilatation of the duct, and severe inflammatory changes limited to the apocrine duct were seen.<sup>41</sup> The adjacent hair follicles, sebaceous glands, and eccrine glands were uninvolved, placing sole responsibility for HS on the apocrine gland.<sup>41,42</sup> The authors postulated that HS was caused by follicular occlusion of the apopilosebaceous gland, possibly by a hormonal mechanism, which resulted in infection of the apocrine gland.<sup>41</sup> Despite voiced

EVALUATION ALGORITHM



**Fig 5.** Algorithm for the evaluation of a patient in whom the diagnosis of hidradenitis suppurativa is being considered. This algorithm is based upon expert opinion and has not been scientifically validated.

objections to the methodology of the study, and only a minority of treated patients who experienced symptoms, the study's conclusions became dogma. Alternatives from the conclusions of Shelly et al developed over several decades.<sup>3,43</sup>

**Evidence for follicular-based pathogenesis.** In 1958, Anderson and Dockerty<sup>3</sup> examined 261 histologic sections from 64 HS patients; they noted a lack of focal inflammation within the apocrine glands. Inflammation of apocrine glands occurred only in

the presence of widespread inflammation, affecting the eccrine glands, hair follicles, sebaceous glands, and small blood vessels.<sup>3</sup> The authors concluded that inflammation of apocrine glands is not essential to HS pathogenesis, occurring only secondarily. Twenty years later, Morgan and Hughes<sup>44</sup> demonstrated no difference in size or density of apocrine glands in HS subjects compared with those of controls.

Despite its prominent role in acne pathogenesis, dysfunctional sebum excretion appears to be unimportant in HS. A study demonstrated similar frequency, density, and pattern of active sebaceous glands in HS patients and control subjects.<sup>45</sup> Furthermore, no significant axillary, genitofemoral, or facial seborrhea was described.

In 1990, Yu and Cook<sup>32</sup> published a histologic study that examined axillary skin specimens from HS patients. They found abnormal, dilated hair follicles in 10 of 12 HS subjects and stratified squamous epithelium-lined cysts or sinuses in the dermis.<sup>32</sup> Laminated keratin was present in all cysts, and half contained hair shafts, suggesting that the cysts were, indeed, dilated hair follicles.<sup>32</sup> Similar dilation of hair follicles with small cysts was found in a recent study in which atypical comedones, similar to those seen in patients with HS, were biopsied.<sup>6</sup> Apocrine gland inflammation was described in four subjects, but only in the background of extensive inflammation involving eccrine glands, hair follicles, and other local structures.<sup>32</sup> They concluded that the abnormal, dilated hair follicles were more prevalent than apocrine inflammation, suggesting that apocrinosis occurs as a secondary phenomenon.<sup>32</sup> In 1995, Attanoos et al<sup>46</sup> described similar findings to those of Yu and Cook<sup>32</sup> in their study of 118 specimens of varying disease duration. A year later, Jemec and Hansen<sup>47</sup> performed a study confirming follicular involvement as the predominant feature in most HS lesions. In fact, in their study, secondary eccrine involvement was more prevalent than secondary apocrine involvement (25% vs 12%).<sup>47</sup> Similar findings were also noted by Heller et al<sup>43</sup> in a 2002 histologic study of HS.

With the results of the previously described studies, many now feel that HS lesions begin with follicular plugging. This plugging presumably results in occlusion and dilation of the pilosebaceous unit, with subsequent rupture (Fig 6). Extrusion of follicular contents, primarily consisting of corneocytes, bacteria, sebum products, and hair into the dermis produce a chemotactic inflammatory response. The resulting influx of neutrophils, lymphocytes, and histiocytes lead to abscess formation.<sup>2,48</sup> This facilitates infection with further suppuration. With recurrence, sinuous, fistulous, tracts evolve.<sup>1,2,32,46,47</sup>

There are several theories as to how follicular plugging may occur. The plugging may be caused by hyper- or parakeratosis or anatomically abnormal follicles with inadequate outlets to the surface.<sup>6</sup> The potential role of abnormal hair follicles, hormones, obesity, and environmental factors will be explored individually later in this section.

An interesting study by Jemec and Gniadecka<sup>49</sup> used ultrasonography to look at hair follicles of patients with HS. He found that even areas of clinically uninvolved skin had follicles with distorted shapes and larger deep diameters; the superficial diameter appeared normal. However, quantitatively, this distorted shape with an increase in width difference was statistically significant only in the genitofemoral paralesional follicles, not in axillary ones.<sup>49</sup> Mean axillary and genitofemoral skin thickness and follicular area were also increased in HS patients, though they were statistically significant only in the axillary skin.<sup>49</sup> Jemec and Gniadecka<sup>49</sup> suggest that increased dermal thickness, resulting in alteration of cutaneous mechanical properties, could be a physical factor in HS development or simply the result of chronic inflammation.

Kurzen et al<sup>50</sup> have suggested that suboptimal biomechanics of keratin found in HS lesions may lead to microtears in the hair follicles. They theorize that this may be the primary event in the disease process.<sup>50</sup> They further speculate that HS might also be caused by an abnormality in inflammatory signals.<sup>50</sup> Sinus tracts were proposed to result from an aberrant epidermal response to injury propagated by stem cell-like cells originating in hair follicles.<sup>50,51</sup>

Larralde et al<sup>6</sup> reported 40 pediatric and adolescent patients with flexural comedones. Biopsies from six patients revealed follicular plugging and infundibular dilation.<sup>6</sup> It was proposed that this entity could be a precursor to HS.<sup>6</sup> As the authors noted, further follow-up and larger studies are necessary before drawing conclusions.

**Nonfollicular-based theories.** Some believe that apocrine glands may yet be proven to play a role in HS lesions. Revuz<sup>50</sup> suggests that an abnormal secretion—either the excess or absence of—could be causing an effect on the acro infundibulum, distal from the gland itself, and therefore was not detected by previous histopathology studies.

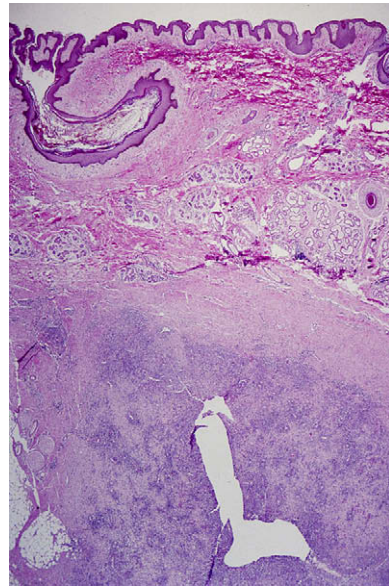
Kurokawa<sup>50</sup> proposes that sinus tract formation is an early feature of HS, not a late one. In fact, he suggests that they arise not from hair follicles but rather from invaginations of the epidermis.<sup>50</sup> These invaginations form infundibulum-like epithelium that protrudes into the reticular dermis as cysts.<sup>50</sup> Resident bacteria, such as CNS can cause adherence

of the epithelium.<sup>50</sup> Therefore, CNS may cause adherence of the epidermis in the adjacent, closed serrated tissue of intertriginous areas, leading to the formation of cysts and HS lesions.<sup>50</sup>

**Genetic factors.** One form of HS may have an AD mode of transmission.<sup>14,52</sup> Fitzsimmons and Guilbert<sup>14</sup> found that 34% of first-degree relatives of probands also had HS. Both males and females were affected via vertical transmission through several generations, consistent with AD inheritance.<sup>7,14</sup> Many of the first-degree relatives were under 20 years of age during the study. It was hypothesized that if the study subjects were followed for longer periods of time, more of them might develop the disease, bringing the percentage of those affected closer to 50%.<sup>14</sup> In support of this supposition, Von der Worth et al<sup>52</sup> restudied these same families 15 years later and did note that additional cases of HS had developed. However, the transmission rate was still less than the 50% rate associated with AD inheritance.<sup>52</sup> They suggested this might be because of their rigid disease definition, incomplete penetrance, and hormonal influences.<sup>52</sup> Jemec<sup>22</sup> suggested that increased familial incidence of HS may be caused by a genetically determined end-organ malfunction that is manifested only under certain conditions.

Genetics studies in a large four-generation Chinese family with HS indicate a locus for the disease on chromosome 1p21.1-1q25.3.<sup>53</sup> However, because of the considerable size of this region, a specific gene was not identified.<sup>53</sup>

**Endocrinologic factors.** The role of hormones in HS is still being defined, with many studies demonstrating conflicting results. Mortimer et al<sup>25</sup> have suggested that HS in females may have an androgenic basis. In their study, women with HS had a higher likelihood of irregular menses, premenstrual HS flares, acne vulgaris, and hirsutism.<sup>25</sup> They also had higher total testosterone concentrations and a higher free androgen index than normal controls.<sup>25</sup> However, Barth et al<sup>35</sup> felt that the increased free androgen index was secondary to low sex hormone binding globulin levels.<sup>35</sup> Sex hormone binding globulin can be decreased in those with excess body weight, and this factor was not corrected for in previous studies.<sup>14</sup> Barth et al<sup>35</sup> compared females with HS to body mass index–matched controls. Both groups were also matched for hirsutism, which was previously thought to be related to higher androgen levels.<sup>35</sup> No difference was observed in plasma testosterone and dehydroepiandrosterone.<sup>35</sup> Another study performed by Barth and Kealey<sup>54</sup> examined histologically isolated apocrine glands from five female patients with HS and age-matched controls.<sup>54</sup> They found that androgen interconverting enzymes



**Fig 6.** Typical histologic changes seen in a patient with hidradenitis suppurativa. Note follicular plugging consistent with comedo formation and underlying deep fibrosis with mixed suppurative and granulomatous inflammatory infiltrates with plasma cells. (Hematoxylin-eosin stain; original magnification:  $\times 4$ .) (Courtesy of Steven R. Feldman, MD, PhD, and Megan Kinney, BS, Graham Dermatopathology Laboratory, Wake Forest University Baptist Medical Center, Winston-Salem, NC.)

in the HS samples were either decreased or were not different from normal controls.<sup>54</sup> These results argue against a basis for hyperandrogenism in women with HS, or exaggerated activity of end-organ androgen interconverting enzymes.<sup>54</sup>

Similarly, Jemec et al<sup>22</sup> found no difference in androgenization (acne, hirsutism, and irregular menstrual periods) between 70 female HS patients and 100 healthy controls.<sup>22</sup> However, Harrison et al<sup>17</sup> demonstrated an association between the absence of a premenstrual HS flare (43% of women in their study) and irregular or anovulatory menstrual cycles, obesity, and acne vulgaris. These patients had lower progesterone levels, higher testosterone levels, higher androstenedione levels, and higher androgen indexes than controls and HS-afflicted women with premenstrual flares.<sup>17</sup> The authors offered no satisfactory explanation for these findings.<sup>17</sup> Further evidence against a role for hyperandrogenism in HS is the notable female predominance. This is quite unlike the situation in acne where a role for androgenic influence correlates well with both an increased incidence and greater severity in males.

Some researchers also suggest that progestogens in oral contraceptives (OCs) play a role in the development of HS.<sup>55</sup> A temporal association between OC initiation and HS onset was shown in

seven patients, most resolving after discontinuation or substitution to a higher estrogen to progestogen ratio OC.<sup>55</sup> However, other studies have not found an association between HS and OCs.<sup>56</sup> Interestingly, case reports of two HS patients noted marked improvement in lesions, tenderness, and joint range of motion during pregnancy; in one patient, disease relapsed after delivery (the other was lost to follow-up).<sup>57</sup> HS may decline substantially following menopause, also suggesting a hormonal role.<sup>57</sup>

Harrison et al<sup>58</sup> demonstrated significantly greater prolactin and thyroid-stimulating hormone responses following thyrotropin-releasing hormone stimulation in HS patients.<sup>58</sup> Increased estrogen activity, which can occur in androgen excess, may result in higher prolactin and thyroid-stimulating hormone stores.<sup>58</sup>

**Bacterial factors.** Many researchers have suggested that bacterial infection is an important factor in HS pathogenesis. Studies on HS bacteriology have produced conflicting results, depending on methods used to obtain bacteria. In older studies, bacteria were collected from the surfaces of HS lesions.<sup>11,59-61</sup> Samples were prone to contamination with skin flora.

Various bacteria have been implicated in cultures taken from the surfaces of HS lesions, including *Streptococcus viridans*, *Staphylococcus aureus*, *S milleri*, anaerobes (Peptostreptococcus species, *Bacteroides melaninogenicus*, and *B corrodens*), coryneform bacteria, and even Gram-negative rods.<sup>4,11,59-62</sup> Gram-negative bacteria, such as *Escherichia coli*, Klebsiella, and Proteus, may be more common in perineal HS.<sup>30,63</sup> *Chlamydia trachomatis* was demonstrated serologically in 6 of 7 patients with perineal HS but was absent in the pus of examined lesions.<sup>64</sup> The fact that so many bacterial species were recovered in these studies and that no single species was dominant suggests that bacteria found on the surface of lesions are secondary colonizers rather than etiologic agents in HS.

A study involving an aspiration technique to sample deeper parts of early HS lesions demonstrated negative cultures in 51% of cases, suggesting that HS is primarily a disease of the follicular epithelium that is secondarily colonized and infected by bacteria.<sup>1,65</sup> The most common bacteria found were *S epidermidis* and *S aureus*.<sup>65</sup> Those with *S aureus* had significantly shorter disease duration.<sup>65</sup> Therefore, *S aureus* may be involved only in early stages of disease, producing early anatomic changes in the hair follicle.<sup>65</sup>

One study circumvented the issues of contamination from superficial colonizing bacteria through the use of a carbon dioxide laser method to ablate HS

tissue in a stepwise manner, collecting bacteria from three subsequently deeper levels.<sup>48</sup> CNS (84%) and *S aureus* (56%) were the most frequently encountered bacteria, followed by Peptostreptococcus species and *Propionobacterium acnes*.<sup>48</sup> All patients had positive cultures in at least one of the three levels examined, with elevated bacterial counts in the deep cultures.<sup>48</sup> Though this is debatable, bacteria recovered from HS lesions more likely play a secondary, rather than a primary, role in HS.<sup>13</sup>

**Environmental factors.** A retrospective study of 45 patients showed that 10 had a history of mechanical irritation before onset of the disease.<sup>61</sup> The mentioned causes of trauma were diverse, and ranged from shaving to friction from a prosthesis.<sup>61</sup> Mustafa et al<sup>8</sup> reported several patients whose HS was worsened by the use of antiperspirants.<sup>8</sup> Some authors have suggested that antiperspirants could exacerbate HS by causing an occlusive film over axillary skin.<sup>8</sup> Antiperspirants may also trigger HS via chemical irritation inducing poral closure or altering axillary flora.<sup>59</sup> Edlich et al<sup>4</sup> also suggested that using safety razors may increase HS susceptibility, enhancing bacterial access via transection of the follicular infundibulum.<sup>4</sup>

A retrospective study by Morgan and Leicester<sup>66</sup> comparing 40 HS patients with 40 age-matched controls demonstrated no significant differences in shaving, chemical depilatories, deodorants, and talcum powder application in both axillary and inguinal regions, as previously suggested.<sup>3,4,11,29,39,61</sup> Older papers suggest that poor hygiene, dyspepsia, constipation, and hemorrhoids could potentially contribute to HS; none of these causes have been proven.<sup>3,8</sup> Obesity may serve to retain sweat, possibly aggravating the role of perspiration as an irritant in HS.

**Host defense factors.** Because of the chronic, relapsing nature of HS, defects in host defense mechanisms are postulated etiologic factors. However, Dvorak et al<sup>67</sup> concluded that host defense mechanisms are intact in HS patients.<sup>67</sup> This group of investigators demonstrated that there were no abnormalities in granulocyte function (chemotaxis, phagocytosis, and intracellular killing of ingested bacteria), cell-mediated immunity studies, or immunoglobulin levels.<sup>67</sup> Hemolytic complement levels were elevated in all subjects, indicating that inflammation may play a primary role in HS.<sup>67</sup> A more recent study demonstrated significant increases in neutrophilic generation of free oxygen radicals after stimulation with phorbol myristate acetate, a protein kinase C activator.<sup>68</sup> This suggests that a neutrophilic functional defect may play a pathogenic role in HS.<sup>68</sup>



Giamarellos-Bourboulis et al<sup>69</sup> studied blood samples from 53 patients with HS and six healthy controls. They found that the percentage of natural killer cells diminishes as time from initial skin lesions increases.<sup>69</sup> They also found lower monocyte responses to bacterial components in patients with HS versus controls.<sup>69</sup> The authors suggest this could be related to an autoimmune mechanism associated with HS, but recognize the need for more research to support their hypothesis.<sup>69</sup>

Recently, a group of disorders characterized by noninfectious recurrent inflammatory episodes, the absence of autoantibodies and antigen-specific T cells, and the presence of polymorphonuclear cell infiltrates have been described. These disorders include familial Mediterranean fever, mevalonate kinase deficiency, tumor necrosis factor–receptor-associated periodic syndrome, cryopyrin-associated periodic syndrome, pyogenic sterile arthritis, pyoderma gangrenosum, acne-like syndromes, recurrent multifocal osteomyelitis, CD, and Behçet disease. It is proposed that HS belongs to this group.<sup>70</sup> Causes of the aforementioned disorders range from defects in inflammatory mediators and receptors to apoptosis.<sup>71-73</sup> HS may share a similar defect.<sup>71</sup>

Hunger et al<sup>74</sup> investigated the role of TLRs in HS using polymerase chain reaction studies and immunohistochemical staining. TLRs are expressed by inflammatory cells and play an integral role in innate immunity.<sup>74</sup> They appear to be important in eliciting an immune response and in the release of proinflammatory cytokines.<sup>74</sup> Compared with normal healthy volunteers, tissue specimens from HS patients show enhanced expression of TLR2 within macrophages and dendritic cells of inflammatory lesions of HS.<sup>74</sup> Increased expression of these compounds has been found in other somewhat similar skin disorders, such as acne vulgaris.<sup>75</sup>

**Pharmacologic factors.** Three reports of HS onset or exacerbation following initiation of lithium therapy suggest that HS may be a possible side effect of this agent.<sup>76-78</sup> The suggested underlying cause is lithium's ability to enhance neutrophil migration and phagocytic ability, increase epithelial cell proliferation, or its ability to cause follicular plugging through its direct effect on follicular keratinocytes (as in acne).<sup>76-78</sup>

**Smoking.** Studies indicate an increased prevalence of smoking among patients with HS.<sup>19,28,79-81</sup> Seventy percent to 88.9% of subjects in some published studies were smokers, suggesting that tobacco is a potential trigger for HS.<sup>79-81</sup> A recent French study showed a strong association with current smoking in self-reported and medically

assessed HS patients.<sup>19</sup> However, this association did not exist for ex-smokers.<sup>19</sup> Researchers have proposed that smoking may alter neutrophilic granulocytes (inducing altered chemotaxis), modify sweat gland activity, and give off toxic metabolites in sweat, all of which could explain this association.<sup>1,82</sup> Parks and Parks<sup>27</sup> believe that nicotine may eventually inhibit normal glandular secretions, subsequently plugging glandular ducts and ultimately producing an inflammatory reaction.<sup>27</sup> However, at least one study fails to support this association.<sup>58</sup>

**Obesity.** Much like smoking, there appears to be a relationship between obesity and HS.<sup>83</sup> In a study by Rompel and Petres,<sup>80</sup> 51.6% of subjects with HS were obese, with 21.5% being markedly obese. Harrison et al<sup>17</sup> found that 77% of males with HS were overweight and 26% were obese, while 69% of females with HS were overweight and 33% were obese.<sup>17</sup> Other studies have reported greater than 75% of HS patients to be obese.<sup>4,42</sup> A significant association with body mass index in medically assessed HS patients was recently reported.<sup>19</sup>

Obesity may aggravate disease in several ways: through sweat retention and maceration, shearing of follicular or ductal outlets, and abnormal hormonal metabolism. In obese patients, the axilla is nestled between the enlarged lateral thoracic wall and the upper arm, resulting in overlapping skin folds and subsequent friction, maceration, and occlusion of the skin.<sup>4</sup> Shearing associated with increased skin-to-skin contact may trigger both follicular hyperkeratosis and follicular plugging via epidermal desquamation.<sup>1,4,9,13,17,30,46</sup> Furthermore, the juxtaposition of skin surfaces may promote keratin hydration within sweat glands. This potentially reduces the diameter of the follicular orifice, further predisposing to poral occlusion.<sup>46</sup> In addition, obesity has been associated with changes in the production, metabolism, and biologic activity of sex hormone binding globulin, androgens, and estrogens, causing a state of relative androgen excess. This androgen excess may result in coarsening of the hair shaft with subsequent follicular plugging.<sup>46</sup>

## PSYCHOLOGICAL AND PHYSIOLOGIC MORBIDITY

### Key points

- **HS patients experience a quality of life worse than those with alopecia, mild to moderate psoriasis, and several other dermatologic conditions**
- **HS results in economic and psychological disability in addition to the physical problems**

von der Werth et al<sup>84</sup> measured morbidity in 114 HS patients using the DLQI questionnaire and demonstrated a total mean score of 8.9, which ranks above alopecia, mild to moderate psoriasis, and several other dermatologic conditions. This high score was heavily influenced by a question rating the level of pain, soreness, stinging, or itching.<sup>84</sup> von der Werth et al<sup>84</sup> explain that the high total mean score is related to a combination of painful eruptions, malodorous discharge, stigma because of the location of lesions in intimate sites, and the lack of medical care related to incorrect diagnosis or the hesitancy of patients to disclose the symptoms or signs of HS.<sup>84</sup>

Several studies have mentioned not only physical but also social and economic disabilities resulting from HS. One case report describes a 46-year-old male with painful draining abscesses of the buttocks, perineum, groin, and axillae, the malodorous discharge of which was so foul that he was forced to leave his job and was deserted by his family.<sup>10</sup> Jemec et al<sup>56</sup> found that patients with HS lost an average of 2.7 work days per year because of HS.<sup>56</sup> Among HS patients, females lost significantly more workdays than males, suggesting that females may have experienced more widespread or more severe disease. The number of births in females with HS was significantly less than in controls.<sup>56</sup> The reason for this is unknown, but could be related to a reluctance of HS patients to participate in intimate activity.

A questionnaire that was distributed to 61 hospitalized HS patients revealed that their reported quality of life was worse than that of many other dermatologic diseases, such as chronic urticaria, psoriasis, atopic dermatitis, and even neurofibromatosis 1.<sup>85</sup> The surveyed study population was comprised of hospital patients, so the study may not be representative of the overall HS population.<sup>85</sup>

Self-reported health was significantly lower in HS patients compared to controls. Five of six patients in a study by Anderson et al<sup>29</sup> were unemployed, economically destitute, and either divorced or reclusive.<sup>29</sup> Anderson and Perry<sup>42</sup> have reported that, in addition to being unemployed and on welfare, many HS patients experience major personality changes, deterioration of the family unit, and may even commit suicide. They go on to state that patients "who are cured of chronic axillary hidradenitis are among the most grateful and appreciative patients one will encounter."<sup>42</sup>

## DISEASE ASSOCIATIONS

### Key point

- **HS is associated with other diseases of the follicular occlusion tetrad, acne vulgaris, KID syndrome, IK, DDD, SAPHO syndrome,**

### **CD, Jackson–Lawler type pachyonychia congenital, reflex sympathetic dystrophy, and FFD, among others**

HS has been associated with many disorders (Table III). The other disorders of follicular occlusion (acne conglobata, dissecting cellulitis of the scalp, and pilonidal cyst) are well known associations with HS, and make up the so-called follicular occlusion tetrad.<sup>86,87</sup> A given patient may have two or more disorders within the tetrad.<sup>86,87</sup> There may also be an association with acne vulgaris (30% in one study), which can be severe in chronic, generalized HS.<sup>3,4,11,17,25,30,61,83</sup> In separate studies by Mortimer et al,<sup>25</sup> Brunsting,<sup>11</sup> and Conway et al,<sup>88</sup> 45%, 50%, and 70% of HS subjects, respectively, had associated acne vulgaris.

Much like acral pustular psoriasis, there appears to be a strong association between obesity, smoking, and HS.<sup>89,90</sup> These two associations were previously discussed at length. In summary, there are a high percentage of HS patients who smoke and/or are obese.<sup>19,79-81,89,90</sup>

HS has been linked to several genetic disorders. Two case reports have described an association between keratitis-ichthyosis-deafness (KID) syndrome and HS.<sup>91,92</sup> KID syndrome is caused by mutations in the connexin-26 gene.<sup>93</sup> Connexin-26 is expressed most commonly on the palms and soles, but also on sweat glands and hair follicles.<sup>94</sup> Hyperproliferative epidermis, resulting from the genetic defect, may predispose to follicular obstruction, with subsequent cyst formation, rupture, and secondary inflammation.<sup>91</sup>

A single case series associating interstitial keratitis (IK) and HS exists. The authors performed a survey of 62 HS patients; in four patients, IK was discovered.<sup>95</sup> HS preceded IK by a mean of 7.2 years.<sup>95</sup> In all patients found to have IK, HS involved multiple sites with a degree of involvement ranging from moderately severe to very severe.<sup>95</sup> These patients required numerous hospitalizations and surgical treatments for their HS.<sup>95</sup> In addition, their ophthalmologic issues were severe and progressive, resulting in marked corneal destruction.<sup>95</sup> The authors postulated that bacterial products within HS lesions might cause IK development related to a toxic reaction, allergic reaction, or endotoxin reaction.<sup>95</sup>

At least eight reports have described the association of DDD and HS.<sup>21,96-103</sup> DDD is a genetic syndrome characterized by acquired, reticulated, symmetrical pigmentary macules of the flexural areas.<sup>98</sup> One report details the presence of HS and DDD in a mother and daughter. The authors propose that this association may be caused by a defect in follicular keratinization.<sup>98</sup>

The association of HS, spondyloarthropathy, and acne conglobata is well described.<sup>104-112</sup> This association is seen predominantly in African American males and equally affects the axial and appendicular joints. It has a chronic course, with temporal concurrence between cutaneous and arthritic flare-ups.<sup>106</sup> Rosner et al<sup>109</sup> suggest that the arthropathy may be a reaction to chronic skin infection. Others have suggested an association with human leukocyte antigen DR-4.<sup>112</sup>

SAPHO syndrome is an infrequently encountered heterogeneous skin–bone disease in which both osseous and articular manifestations occur along with skin manifestations.<sup>113,114</sup> Most cases have been described in Japan, Scandinavia, Germany, and France.<sup>114</sup> Kahn et al,<sup>115</sup> Khan and Chamot,<sup>116</sup> Chamot and Khan,<sup>117</sup> and Khan<sup>118</sup> have together proposed three diagnostic criteria for SAPHO syndrome: (1) multifocal noninfectious osteomyelitis, with or without skin manifestations; (2) sterile acute or chronic joint inflammation associated with (a) pustular psoriasis or palmoplantar pustulosis, (b) acne, or (c) HS; and (3) sterile mono- or polyosteoitis in the presence of one of the aforementioned skin manifestations. According to Kahn et al<sup>115</sup> and Khan and Chamot,<sup>116</sup> any one of the above criteria is sufficient for a SAPHO diagnosis.

In one study, 12 patients with SAPHO from three hospitals were analyzed; seven had HS as part of their syndrome.<sup>114</sup> All required extensive surgery for drainage and/or sweat gland resection and antibiotic and nonsteroidal antiinflammatory drug therapy.<sup>114</sup> Of the seven patients with HS, six were African American, suggesting a possible SAPHO–HS predisposition in that population.<sup>114</sup> The groin was affected in all seven patients and the axillae in six; two patients were affected perirectally and around the neck, and one had affected breasts.<sup>114</sup> Three of the seven patients had pyoderma gangrenosum and HS (associated with more aggressive SAPHO), three patients had life-threatening complications, including Gram-negative bacteremia, and two patients had a polyclonal gammopathy (associated with dense plasma cell infiltrates in skin and synovial biopsies).<sup>114</sup> In addition, patients with the most severe HS had more erosive arthropathy.<sup>114</sup> It appears that HS in the presence of SAPHO may be more deleterious than HS alone. Another seemingly related disease complex known as pyogenic arthritis, pyoderma gangrenosum, and acne (PAPA) syndrome has also been associated with HS.<sup>119</sup>

Several case reports and studies have suggested an association between HS and CD.<sup>28,120-122</sup> In the largest of these reports, 24 of 61 (38%) HS patients also had a CD diagnosis. In most of these cases, CD

**Table III.** Diseases associated with hidradenitis suppurativa

Common associations	Rare associations
Acne conglobata	Acanthosis nigricans
Acne vulgaris	Bazex-Dupre-Christol syndrome
Crohn disease	Dowling–Degos disease
Dissecting cellulitis of the scalp	Fox–Fordyce disease
Obesity	Interstitial keratitis
Pilonidal disease	Keratitis-ichthyosis-deafness syndrome
Smoking	Pachyonychia congenita
	PAPA syndrome
	Pyoderma gangrenosum
	Reflex sympathetic dystrophy
	SAPHO syndrome
	Scrotal elephantiasis

PAPA, Pyogenic arthritis, pyoderma gangrenosum, and acne; SAPHO, synovitis, acne, pustulosis, hyperostosis, and osteitis.

affected only the large bowel, and its diagnosis preceded that of HS by 3.5 years; diagnosis of HS preceding that of CD has also been reported.<sup>120,122</sup> HS affected the perineal and perianal area in all patients and secondary sites in 83% of patients.<sup>120</sup> Perianal swelling and inflammation associated with CD may trigger development of perineal HS in those already at risk. Of course, this does not explain the frequent presence of axillary, groin, and buttock disease.<sup>120</sup>

Todd et al<sup>123</sup> reported five of six family members with Jackson–Lawler type pachyonychia congenita and concurrent HS. Pachyonychia congenita is an autosomal dominant genodermatosis affecting ectodermal development.<sup>124,125</sup> The Jackson–Lawler subtype is characterized by natal teeth presence, steatocystoma multiplex, and multiple epidermoid cysts on the trunk, axillae, neck, and scalp, in addition to pachyonychia.<sup>124,125</sup> The patients may also have palmar and plantar hyperkeratosis and blister development, hyperhidrosis, and follicular hyperkeratosis.<sup>124,125</sup> Five of the six affected family members gave a history of recurrent abscesses in the axillae, groin, and anogenital areas.<sup>123</sup> Three patients had evidence of scarring, nodules, and sinus tract formation in the axillae.<sup>123</sup> Genetic, follicular, and/or inflammatory factors may explain the association.<sup>123</sup>

One report describes an association between reflex sympathetic dystrophy or complex regional pain syndrome type 1 and HS.<sup>126</sup> The authors suggest HS as a consideration when searching for an etiology of new-onset reflex sympathetic dystrophy.<sup>126</sup> Inflammatory stimulation may be a possible explanation for this association.<sup>126</sup> More reports are necessary before one can put more confidence in this association.

**Table IV.** Complications associated with hidradenitis suppurativa

Anal, urethral, and rectal strictures and fistulas
Anemia
Contractures and limb mobility limitations
Cutaneous squamous cell carcinoma
Increased risk of other malignancy
Lumbosacral epidural abscess
Sacral bacterial osteomyelitis

Lastly, Fox-Fordyce disease (FFD) is a rare pruritic disorder characterized by eruptions of small, discrete, flesh-colored papules located in the axillary, areolar, pubic, and sternal regions. Concurrent HS and FFD was described in three African American females.<sup>127</sup> The authors attributed this association to follicular obstruction, which is present in both disorders.<sup>127</sup>

## PROGNOSIS AND DISEASE COMPLICATIONS

### Key points

- **The risk of SCC and other malignancies may be increased in those with HS**
- **Contractures, strictures, serious infection, and anemia are also potential sequelae**

HS can cause significant complications (Table IV). There have been numerous reports that have associated HS with SCCs of the skin.<sup>24,86,101,128-155</sup> The ratio of SCC in HS favors males (4:1).<sup>128</sup> Sixty-one percent of cases were located in the perineum or buttocks; there were no reports of SCC in axillary HS.<sup>128</sup> Forty-eight percent of these patients died within 2 years of SCC recognition.<sup>128</sup> The mean duration of HS before SCC diagnosis was 25 years.<sup>128</sup> A study of 125 patients with perianal or gluteal HS found that four (3.2%) of these patients had SCC; all four had HS for 19 years or longer.<sup>33</sup> In another study, two of 64 (3.2%) perianal HS patients had evidence of SCC.<sup>3</sup> The actual incidence of SCC in HS patients may be lower than these numbers suggest because of the selection bias inherent in these types of studies. In reporting two cases of anogenital verrucous carcinoma, Brown et al<sup>148</sup> and Cosman et al<sup>156</sup> proposed that human papillomavirus might be an important factor in the development of malignancy.

A large retrospective study with more than 2000 subjects revealed that those with HS had a 50% increased risk in overall incidence of malignancy.<sup>157</sup> A 4.6-fold increase in cutaneous SCC was observed in these patients.<sup>157</sup> Other significant malignant associations included buccal cancer and primary liver cancer, but Lapins et al<sup>157</sup> explain that confounding by smoking and alcohol abuse may account for this.

The excessive scarring and fibrosis produced by HS lesions can lead to contractures and limitations in limb mobility, especially in the axilla. In addition, inflammation and scarring in the genitofemoral region may predispose to anal, urethral, and rectal strictures.<sup>15</sup> Urethral fistulas and massive scrotal and vulvar lymphedema have also been reported in patients with HS.<sup>31,158</sup> Anal fistulas are a consequence of longstanding perianal HS.<sup>28</sup> Scarring and subsequent fixation of anal sphincters can potentially result in fecal incontinence.<sup>24</sup>

There is a risk of serious infection depending on the location of lesions. One case describing a lumbosacral epidural abscess in a woman with a sacral decubitus ulcer caused by HS and another case of sacral bacterial osteomyelitis have been reported.<sup>29,159</sup>

Finally, HS has been associated with anemia. A study by Tennant et al<sup>62</sup> involving 42 consecutive cases of HS confirmed that 10 of these cases (23.8%) had marked anemia with hemoglobin levels below 10.0 g/100 cc; another 10 patients had milder anemia.<sup>62</sup> All cases of marked anemia had severe HS of the buttocks and groin for more than 2 years.<sup>62</sup> Tennant et al<sup>62</sup> hypothesize that the anemia in HS is secondary to chronic infection. Many of the patients in this study also had elevated erythrocyte sedimentation rates and gamma-globulin.<sup>62</sup> A report about one male who died from perineal/perianal HS complications described severe hypochromic anemia, hypoalbuminemia, hypergammaglobulinemia, amyloidosis, and fistulas to the rectum, urethra, urinary bladder, and peritoneum.<sup>160</sup>

## TREATMENT

### Key points

- **There is no uniformly effective single therapy for HS; therefore, clinicians will likely have to try an array of different treatment modalities depending on the patient's disease**
- **For patients with extensive disease, wide excision can dramatically improve the patients' quality of life**
- **Most of the listed therapies are ones that dermatologists possess intimate knowledge of and are thus in the best position to treat this debilitating disorder.**

### Antibiotics

Treatment for HS can be broadly grouped into either surgical or medical therapies. Antibiotic therapy for HS may be administered topically or systemically.<sup>161</sup> Clindamycin is the best-studied of the topical medications. A randomized controlled trial

was conducted with 27 patients who used topical clindamycin 1% solution twice daily for 12 weeks.<sup>162</sup> Significant reductions in abscesses and pustules were seen, but not inflammatory nodules.<sup>162</sup> A randomized trial comparing topical clindamycin 1% solution twice daily to 500 mg of tetracycline twice daily was conducted by Jemec and Wendelboe.<sup>37</sup> They found a significant abscess reduction occurred with both treatments during the first 3 months.<sup>37</sup> More than 3 months were needed to appreciate nodule reduction.<sup>37</sup> No significant difference in efficacy between topical clindamycin and oral tetracycline was demonstrated.<sup>37</sup>

A small, uncontrolled, retrospective case series examining combination oral clindamycin and rifampicin found that 8 of 14 patients achieved 1- to 4-year long remissions after 10 weeks of combination therapy.<sup>163</sup> Another two patients achieved remission after minocycline was substituted for clindamycin.<sup>163</sup> Four patients discontinued therapy because of diarrhea.<sup>163</sup>

Kaur and Lewis<sup>164</sup> published a retrospective review of five patients treated with dapsone.<sup>164</sup> They asked the patients to retrospectively complete a questionnaire regarding lesion soreness, frequency, and duration.<sup>164</sup> They reported improvement in all five patients within 4 to 12 weeks of beginning therapy, at daily doses ranging from 25 to 150 mg.<sup>164</sup> All patients required maintenance therapy between 50 and 150 mg daily.<sup>164</sup> The median follow-up was 24 months.<sup>164</sup> No patients had significant side effects.<sup>164</sup> They hypothesize that dapsone works for HS as it does in other inflammatory dermatoses (ie, by inhibiting neutrophil chemotaxis).<sup>164</sup> Though the number of good clinical studies is small, antibiotic therapy is, among almost all clinicians, the mainstay of initial therapy for HS.

### Retinoids

Boer and van Gemert<sup>165</sup> published a retrospective chart review of 64 patients treated with isotretinoin (mean dose, 0.56 mg/kg) for 4 to 6 months.<sup>165</sup> Unfortunately, results were disappointing for a disease with a proposed pathogenesis similar to acne vulgaris. More than one quarter (29.4%) of patients did not complete the 4-month minimum study regimen.<sup>165</sup> Patients mostly dropped out because of lack of efficacy, adverse side effects, or a combination of both.<sup>165</sup> Less than one quarter (23.5%) of patients developed disease clearance; none of them, however, had severe disease at baseline.<sup>165</sup> In 11 of 16 responders, positive results persisted for a mean of 57 months.<sup>165</sup> The 32 patients with refractory disease were, justifiably, dissatisfied with therapy.<sup>165</sup>

### Hormones

Several trials using antiandrogen therapy have been conducted. In a randomized trial comparing ethinyloestradiol 50 mg/cyproterone acetate 50 mg to ethinyloestradiol 50 mg/norgestrel 500 mg in 24 patients, both regimens produced improvement in disease activity.<sup>166</sup> Seven patients cleared with therapy, remaining disease-free 18 months posttreatment.<sup>166</sup> In addition, five patients improved, four patients remained unchanged, and two patients worsened after treatment.<sup>166</sup> There was no significant difference in treatment groups, with both regimens resulting in free androgen index reduction.<sup>166</sup> Sawers et al<sup>167</sup> published a case series examining four chronic HS patients receiving cyproterone acetate 100 mg daily.<sup>167</sup> HS was controlled in all patients; disease worsened when the dosage was reduced to 50 mg daily.<sup>167</sup> In a seven-patient trial examining the use of daily finasteride 5 mg (a type II 5- $\alpha$ -reductase inhibitor), complete healing of the lesions occurred in three patients; the remaining patients demonstrated reductions in suppuration and active inflammation.<sup>168</sup> In two patients, disease remission occurred for 8 to 18 months following treatment discontinuation.<sup>168</sup> Two patients developed HS recurrence 1 month posttreatment. One patient had bridging scars with recalcitrant pus pockets, prompting referral to surgery.<sup>168</sup> Another patient discontinued therapy because of pruritus.<sup>168</sup> Two patients in the study developed breast tenderness, one of which had persistent pain for a full year after discontinuing her medication.<sup>168</sup>

A retrospective chart review of 64 females with HS found that the response to antihormonal therapy was superior to that of antibiotics (55% vs 25%).<sup>169</sup> Of course, drawing conclusions from retrospective studies such as this should be done with caution.

### Immunosuppressive and antiinflammatory agents

Immunosuppressive therapy has been used to target the inflammatory stages of HS. A patient with chronic granulomatous disease and HS who underwent a renal transplant experienced dramatic lesion improvement in the HS posttransplant.<sup>170</sup> His medication regimen included prednisone 5 mg every other day, tacrolimus 1 mg daily, and mycophenolate mofetil 500 mg twice daily.<sup>170</sup> Another case report detailed a male with intractable pyoderma gangrenosum and HS who was treated with cyclosporine 4.5 mg/kg/day.<sup>171</sup> Both his pyoderma gangrenosum and HS dramatically improved.<sup>171</sup> Other reports of patients taking cyclosporine have found similar improvements, but relapse tends to occur after drug

discontinuation.<sup>172</sup> Another case report describes a patient with CD and HS treated with azathioprine, methylprednisolone, and isotretinoin.<sup>173</sup> Both diseases went into remission following treatment. Jemec<sup>174</sup> performed a study on three patients using 12.5 mg or 15 mg of methotrexate weekly for up to 6 months.<sup>174</sup> No benefit was found.<sup>174</sup>

The TNF- $\alpha$  (TNF $\alpha$ ) inhibitors infliximab and etanercept have also produced favorable outcomes in HS.<sup>70,121,130,160,175-190</sup> Infliximab was first shown to be efficacious in HS patients with CD.<sup>189</sup> A long-term study of 10 patients looking at efficacy of a single course of three infliximab infusions at 0, 2, and 6 weeks demonstrated improvement in all patients following therapy.<sup>176</sup> The mean DLQI demonstrated improvement a year after initiating therapy as noted by their scores decreasing from 18.4 to 9.1.<sup>176</sup> However, interpatient results varied markedly.<sup>176</sup> Four patients had disease recurrence after 1 year, while two patients finished with scores only slightly below their pretreatment baseline.<sup>176</sup>

Brunasso et al<sup>191</sup> recently reported long-term results in seven patients with a mean follow up of 119 weeks. They initially found impressive results 3 months after beginning therapy, with a mean pain reduction of 96.2%, a mean reduction of serous and purulent discharge of 69.5%, and a mean area reduction of 7%.<sup>191</sup> Unfortunately, improvement began to decrease linearly over time, such that after 24 months, the mean pain reduction was 34.8%, the mean discharge reduction was 30.5%, and the mean area reduction was 1.25%.<sup>191</sup> Other reports have described variable patient responses and significant adverse events, including lupus-like reactions, hypersensitivity reactions, abdominal pain secondary to colon cancer, multifocal motor neuropathy with conduction block, tuberculosis, and anaphylactic shock.<sup>176,180,181,188</sup>

Etanercept appears to have similar efficacy to infliximab, with the obvious advantage of subcutaneous injections instead of intravenous infusions. A study of six patients receiving etanercept 25 mg twice weekly demonstrated initial responses 16 days (mean) after therapy initiation.<sup>184</sup> At 24 weeks post-initiation, mean self-reported DQI scores improved by 64%.<sup>184</sup> A single case report published by Zangrilli et al<sup>192</sup> described improvement in a patient treated with etanercept that was measured by a self-reported DQI and visual analogue pain score.<sup>192</sup> The authors claimed the long-standing disease improvement occurred up to 48 weeks after the initiation of therapy; objective data from these claims, however, were not reported.<sup>192</sup>

Adalimumab, another TNF $\alpha$  inhibitor, has been documented as useful for HS treatment in two case

reports. In one case, adalimumab 40 mg every other week successfully improved a patient with HS refractory to antibiotics, radiation therapy, and aggressive surgery.<sup>193</sup> The patient experienced prompt improvement after one treatment; no long-term results were reported. The other report details a patient with seronegative arthritis and HS.<sup>194</sup> He improved after 1 month of 40 mg injections every other week. After another month of treatment, the patient noted that his condition worsened; his dose was increased to 40 mg weekly. The patient's pain and symptoms returned after he stopped the medication because of insurance issues.

There is not enough information available to assess the true risks of TNF $\alpha$  inhibitors used in HS patients. However, a metaanalysis of nine placebo-controlled trials using etanercept or adalimumab in patients with rheumatoid arthritis demonstrated significantly increased malignancies in those receiving high doses of medication (6 mg/kg of infliximab every 8 weeks or 40 mg of adalimumab every other week) than in those receiving low doses of medication (3 mg/kg of infliximab every 4 weeks or 20 mg of adalimumab weekly).<sup>195</sup> Infusion-related reactions occur in up to 16% of patients receiving infliximab for psoriasis.<sup>196</sup> These reactions include urticaria, pruritus, hypotension, and anaphylaxis.<sup>196</sup> All TNF $\alpha$  inhibitors are associated with an increased risk of infection.<sup>196</sup> Upper respiratory tract infections are the most common.<sup>196</sup> Serious infections are uncommon, unless the patient is already predisposed because of preceding immune suppression.<sup>196</sup> Nevertheless, they have been reported with the use of all TNF $\alpha$  inhibitors. Infections include mycobacterium tuberculosis, coccidioidomycosis, cryptococcosis, aspergillosis, listeriosis, candidiasis, pneumocystis, and histoplasmosis.<sup>196</sup> Interestingly, these infections may be less common in those treated with etanercept rather than infliximab or adalimumab.<sup>197-199</sup> Other problems, such as congestive heart failure exacerbation, lupus-like syndrome, hepatic disease, lymphoma, melanoma and nonmelanoma skin cancers, and hematologic disease have been reported.<sup>196</sup>

Other nonsteroidal antiinflammatory agents have been used in the treatment of HS. Most of these are supported only by anecdotal data, but among these there is particular enthusiasm for the use of oral zinc.<sup>200</sup> Further studies are obviously necessary before a role for zinc or other nonsteroidal antiinflammatory drugs can be realistically determined.<sup>200</sup>

Corticosteroids also have a role to play in the treatment of HS. Publications detailing their use are sparse and often in combination with other medications.<sup>201-205</sup> Corticosteroids are typically administered either intralesionally or orally.<sup>201-205</sup> Dosing

regimens vary.<sup>201-205</sup> Dramatic improvement may be seen initially, but their efficacy seems to be lost shortly after their discontinuation. They can be useful in treatment of flares, but their side effects limit long-term use.

### Neurotoxins

A single case report has been published on the use of botulinum toxin for the treatment of HS.<sup>206</sup> The authors performed a series of intradermal injections during a single treatment session. The patient's inflammatory lesions resolved for 10 months following the treatment.<sup>187</sup> The authors suggest that botulinum toxin may decrease apocrine gland secretion, thereby limiting tendency towards follicular rupture.<sup>187</sup>

### Radiotherapy

Radiation therapy for HS was extensively used in the past.<sup>207-209</sup> Techniques and responses have varied widely. Radiotherapy has been suggested as efficacious for early lesions of HS but not for sinuses.<sup>207</sup> In a study by Frohlich et al,<sup>210</sup> 38% of patients treated had complete resolution of their symptoms. Forty percent more had clear improvement.<sup>210</sup> Problems with poor tissue healing were noted.<sup>210,211</sup> Zeligman<sup>207</sup> reported that a single treatment with superficial x-rays was highly efficacious in his series of five patients. Hair follicle destruction is the suggested mechanism of action.<sup>207</sup>

### Light, radiofrequency, and other procedures

Cryosurgery has been studied as a potential HS treatment. Eight of 10 treated patients improved.<sup>212</sup> Unfortunately, complications were significant. Six patients developed infections and five developed ulcers.<sup>212</sup> The average posttreatment healing time was 25 days.<sup>212</sup>

Carbon dioxide laser therapy has been used successfully in HS.<sup>213-215</sup> Lapins et al<sup>214</sup> treated 31 patients, reporting only four recurrences in targeted areas. However, 12 patients developed recurrences at sites more than 5 cm from the treatment area; 25 patients had recurrences at distant anatomic sites.<sup>214</sup> Focused mode laser therapy was performed, and tissue was ablated at least until the subcutaneous plane.<sup>214</sup> The procedure was similar to standard scalpel surgery in its endpoint.

Iwasaki et al<sup>216</sup> published a case report of a 17-year-old male who responded well to three treatments with a nonablative radiofrequency device. His efficacy was based on a diary of daily symptoms.<sup>216</sup> The patient noted an improvement in lesion number, quality, and duration.<sup>216</sup> Peak improvement was noted 2 to 3 weeks following treatment. Six months

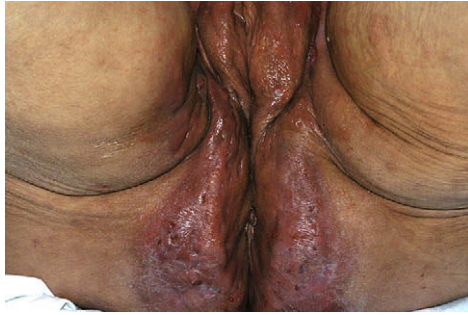after his third treatment, the patient continued to do well.<sup>216</sup>

Photodynamic therapy has had mixed results. Gold et al<sup>217</sup> noted a 75% to 100% improvement in four study patients. The last patient follow-up was 3 months posttreatment.<sup>217</sup> No specific outcome measures were discussed in the paper.<sup>217</sup> Rivard and Ozog<sup>218</sup> reported two patients who improved with photodynamic therapy.<sup>218</sup> Once again, no outcome measures were mentioned.<sup>218</sup> Ultimately, disease resumed in both patients following therapy.<sup>218</sup> Strauss et al<sup>219</sup> reported no improvement in four patients treated with photodynamic therapy; two had worsened 8 weeks posttreatment. Two patients—50% of the study population—dropped out before completing the study.<sup>219</sup>

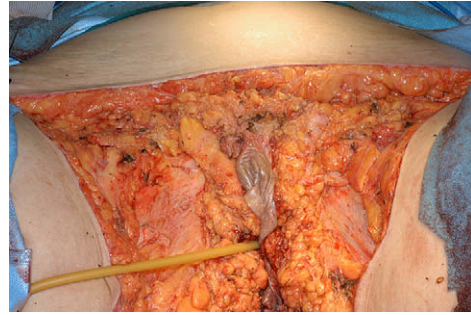
### Surgery

Surgery is largely regarded as one of the most effective treatments for intractable HS (Fig 7, 8, and 9). Surprisingly, this supposition lacks substantive randomized controlled trials. Treatment efficacy varies by location. A study of 82 patients with 118 radical excisions revealed recurrence rates of 0% in the perianal area and 3% in the axillary area.<sup>220</sup> The inframammary and inguinoperineal areas, however, suffered from recurrence rates of 37% and 50%, respectively.<sup>220</sup> Overall, 91% of patients were pleased with their results at follow-up.<sup>220</sup> Unfortunately, 25% had recurrence of disease at a distant location.<sup>220</sup> Operative complications occurred in 12% of subjects and included skin graft failure (45% of applied grafts), ischemic necrosis of a myocutaneous flap, limb vein thrombosis, anemia, transient edema, and hypertrophic scarring with pain requiring reoperation.<sup>220</sup> A retrospective review of 72 patients found that recurrence rates were as high as 54% following excision down to fascia with primary closure.<sup>221</sup> This figure dropped dramatically when flaps (19%) or split-thickness grafts (13%) were used for closure.<sup>221</sup> Similar results were later reported by the same author examining another cohort of patients.<sup>222</sup> Recurrence requiring reoperation after primary closure was 69.88% but was 0% for closure by flap and split-thickness graft, respectively.<sup>222</sup> The lower recurrence rates with flaps and grafts probably reflect more extensive tissue removal than the particular closure techniques.

Ritz et al<sup>139</sup> compared recurrence rates of HS after incision and drainage, limited excision, and radical wide excision. They found 100% recurrence after a median of 3 months in the drainage group, 42.8% recurrence in the local excision group (median time, 11 months), and 27% recurrence in the wide excision group (median time, 20 months).<sup>139</sup>



**Fig 7.** Patient with Hurley stage III hidradenitis suppurativa before wide excision. (Courtesy of Hope Haefner, MD, University of Michigan, Ann Arbor, MI.)



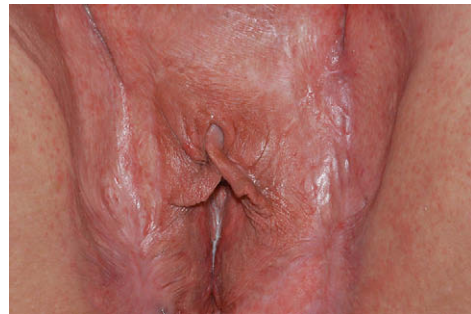**Fig 8.** Same patient as seen in Fig 7 immediately following wide excision. (Courtesy of Hope Haefner, MD, University of Michigan, Ann Arbor, MI.)

A study comparing grafting to second intention healing following axillary excision of HS was performed in 10 patients with 20 treated axillas.<sup>223</sup> The median time to complete healing was 7 weeks for the grafted sites and 12 weeks for the second intention sites.<sup>223</sup> Seven of ten patients preferred the second intention healing method because of ease of use, limb mobility, lack of painful donor site, and comfort.<sup>223</sup> Two patients preferred the more rapid healing of the graft site and one patient disliked both methods.<sup>223</sup>

The laying open of sinus tracts, possibly as a staged procedure, is advocated by some as a compromise between the lack of efficacy of simple incision and drainage procedures or limited excision versus the morbidity of radical removal of all regional tissue. Evidence to support this supposition is limited to a single case series of four patients and a letter to the editor.<sup>83,202</sup>

### APPROACH TO TREATMENT

By this point, readers have likely come to understand the limited nature of clinical treatment trials that have been performed on patients with HS. There is no overwhelmingly effective treatment for patients with any stage of disease with HS. Therefore, most physicians will be forced to try a variety of different therapeutic modalities. We suggest a treatment algorithm based upon the Hurley classification or a tiered approach (Table V). Those with more severe disease may benefit from more aggressive therapy earlier rather than after a prolonged trial of less aggressive treatment modalities, or they may need multiple simultaneous treatment methods. It should be noted that the algorithm is not meant to suggest that patients with severe disease should not try one of the therapies listed for disease of more limited scope, but that more aggressive treatment might be helpful at the outset. Every patient is different and will require a unique approach depending on their disease and tolerance



**Fig 9.** Same patient as seen in Figs 7 and 8, 7 months after wide excision and split-thickness grafting. (Courtesy of Hope Haefner, MD, University of Michigan, Ann Arbor, MI.)

for risk. The scheme is also limited in that patients may not always fit exclusively into one Hurley stage, but the simplicity of the system should at least help the clinician formulate an initial approach to treatment.

For patients with abscesses, but no cicatrization or sinuses (Hurley stage I), antibiotics are a good first-line therapy. Limited lesions can be injected with corticosteroids, and flares can be addressed with short courses of oral or intramuscular corticosteroids. If this regimen is unsuccessful, zinc—or, if the patient is female and of nonchildbearing age, antiandrogen therapy—may be employed. If an insufficient response is obtained following these modalities, one of the other higher order methods may be chosen.

Patients with one or more widely separated recurrent abscesses with sinus tract formation and scars (Hurley stage II), or who have failed the first-line therapies, may need more aggressive treatment than those with early-stage lesions. Treatments that carry more risk may be worth trying depending on the severity of the patient's disease course. Long-term immunosuppressive therapy or surgical therapies, such as limited excisions or the laying open of sinus tracts, may be helpful.



**Table V.** Treatment suggestions for hidradenitis suppurativa based upon Hurley stage or initial therapy

Hurley stage I disease or first-line therapy	Hurley stage II disease or second-line therapy	Hurley stage III disease or third-line therapy
Antibiotics, either topical or systemic (A)	CO <sub>2</sub> laser ablation (A)	Radiation therapy (A)
Hormonal therapy (A)	Immunosuppressive therapies (A)	Wide excision (A)
Retinoids (A)	Limited excisions (A)	Laying open of sinus tracts (C)
Zinc (A)	Radiation therapy (A)	
Cryotherapy (B)	Radiofrequency treatment (C)	
Botox (C)		
Radiofrequency treatment (C)		
Short-term corticosteroids (C)		

Clinical recommendations are shown in parentheses after each table entry and are classified as follows: (A) recommendation based on consistent and good quality patient-oriented evidence; (B) recommendation based on inconsistent or limited quality patient-oriented evidence; and (C) recommendation based on consensus, opinion, or case studies.

**Table VI.** General treatment suggestions for all hidradenitis suppurativa patients regardless of Hurley stage

Avoidance of tight-fitting clothing
Nonnarcotic analgesics
Reassurance
Smoking cessation
Stress management
Support group referral
Weight loss

Patients with multiple interconnected sinus tracts and abscesses throughout an entire region (Hurley stage III) may have such debilitating disease that only surgery can adequately address their symptoms. Wide excision of all the patients' affected tissue and the underlying sinus tracts is the most effective treatment for these patients. Though disease can recur in locations not treated by surgery and sometimes even within the treated area itself, almost all patients have substantial improvement following the procedure. Many methods have been discussed to close the wound, ranging from skin flaps, grafts, and even second intention healing. What matters most is that the diseased tissue is removed aggressively enough to minimize recurrence. For patients who may not want, or tolerate, a surgical procedure, one of the first- or second-tier therapies may be chosen (Table V).

In addition to the approach discussed above, there are recommendations that should be made to all patients regardless of their Hurley classification (Table VI). Because both smoking and obesity may play a role in the pathogenesis of HS, smoking cessation and weight loss should be encouraged. Avoidance of tight fitting clothing has been suggested to help patients affected by HS. Support group referral is essential, because this can be a very embarrassing and debilitating disorder.

## CONCLUSION

The prevalence of HS may equal or even surpass that of psoriasis, yet it receives only a fraction of the attention and scholarly contributions. Though no overwhelmingly effective treatments have been described, novel therapies are emerging. Many—if not all—of these therapies are well known to dermatologists; therefore, we should play a lead role in managing this debilitating disorder. As our understanding of this disorder grows, so will our treatment options. Readers may find the book by Jemec et al<sup>224</sup> helpful.

We thank Maxwell A. Fung, MD, for writing the histopathologic description for Fig 6; Steven R. Feldman, MD, and Megan Kinney, BS, for providing the pathologic image; Hope Haefner, MD, and Michael S. Wong, MD, for providing some of the clinical images; and Miki Garcia, MD, for her work editing the manuscript.

## REFERENCES

- Slade DE, Powell BW, Mortimer PS. Hidradenitis suppurativa: pathogenesis and management. *Br J Plast Surg* 2003;56:451-61.
- Mortimer PS, Lunniss PJ. Hidradenitis suppurativa. *J R Soc Med* 2000;93:420-2.
- Anderson MJ Jr, Dockerty MB. Perianal hidradenitis suppurativa: a clinical and pathologic study. *Dis Colon Rectum* 1958;1:23-31.
- Edlich RF, Silloway KA, Rodeheaver GT, Cooper PH. Epidemiology, pathology, and treatment of axillary hidradenitis suppurativa. *J Emerg Med* 1986;4:369-78.
- Habif TP. *Clinical dermatology: a color guide to diagnosis and therapy*. New York: Mosby; 2004.
- Larralde M, Abad ME, Munoz AS, Luna P. Childhood flexural comedones: a new entity. *Arch Dermatol* 2007;143:909-11.
- Brown TJ, Rosen T, Orengo IF. Hidradenitis suppurativa. *South Med J* 1998;91:1107-14.
- Mustafa EB, Ali SD, Kurtz LH. Hidradenitis suppurativa: review of the literature and management of the axillary lesion. *J Natl Med Assoc* 1980;72:237-43.
- Jansen T, Plewig G. What's new in acne inversa (alias hidradenitis suppurativa)? *J Eur Acad Dermatol Venereol* 2000;14:342-3.
- Ramasasthy SS, Conklin WT, Granick MS, Futrell JW. Surgical management of massive perianal hidradenitis suppurativa. *Ann Plast Surg* 1985;15:218-23.

11. Brunsting HA. Hidradenitis suppurativa; abscess of the apocrine sweat glands. A study of the clinical and pathologic features, with a report of twenty-two cases and a review of the literature. *Arch Derm Syphilol* 1939;39:108-20.
12. Ching CC, Stahlgren LH. Clinical review of hidradenitis suppurativa: management of cases with severe perianal involvement. *Dis Colon Rectum* 1965;8:349-52.
13. Wiseman MC. Hidradenitis suppurativa: a review. *Dermatol Ther* 2004;17:50-4.
14. Fitzsimmons JS, Guilbert PR. A family study of hidradenitis suppurativa. *J Med Genet* 1985;22:367-73.
15. Thornton JP, Abcarian H. Surgical treatment of perianal and perineal hidradenitis suppurativa. *Dis Colon Rectum* 1978;21:573-7.
16. Mengesha YM, Holcombe TC, Hansen RC. Prepubertal hidradenitis suppurativa: two case reports and review of the literature. *Pediatr Dermatol* 1999;16:292-6.
17. Harrison BJ, Read GF, Hughes LE. Endocrine basis for the clinical presentation of hidradenitis suppurativa. *Br J Surg* 1988;75:972-5.
18. Lewis F, Messenger AG, Wales JK. Hidradenitis suppurativa as a presenting feature of premature adrenarche. *Br J Dermatol* 1993;129:447-8.
19. Revuz JE, Canoui-Poitrine F, Wolkenstein P, Viallette C, Gabison G, Pouget F, et al. Prevalence and factors associated with hidradenitis suppurativa: results from two case-control studies. *J Am Acad Dermatol* 2008;59:596-601.
20. Jemec GB, Heidenheim M, Nielsen NH. The prevalence of hidradenitis suppurativa and its potential precursor lesions. *J Am Acad Dermatol* 1996;35:191-4.
21. Lookingbill DP. Yield from a complete skin examination. Findings in 1157 new dermatology patients. *J Am Acad Dermatol* 1988;18:31-7.
22. Jemec GB. The symptomatology of hidradenitis suppurativa in women. *Br J Dermatol* 1988;119:345-50.
23. Fitzsimmons JS, Guilbert PR, Fitzsimmons EM. Evidence of genetic factors in hidradenitis suppurativa. *Br J Dermatol* 1985;113:1-8.
24. Williams ST, Busby RC, DeMuth RJ, Nelson H. Perineal hidradenitis suppurativa: presentation of two unusual complications and a review. *Ann Plast Surg* 1991;26:456-62.
25. Mortimer PS, Dawber RP, Gales MA, Moore RA. Mediation of hidradenitis suppurativa by androgens. *Br Med J (Clin Res Ed)* 1986;292:245-8.
26. Culp CE. Chronic hidradenitis suppurativa of the anal canal. A surgical skin disease. *Dis Colon Rectum* 1983;26:669-76.
27. Parks RW, Parks TG. Pathogenesis, clinical features and management of hidradenitis suppurativa. *Ann R Coll Surg Engl* 1997;79:83-9.
28. Wiltz O, Schoetz DJ Jr, Murray JJ, Roberts PL, Collier JA, Veidenheimer MC. Perianal hidradenitis suppurativa. The Lahey Clinic experience. *Dis Colon Rectum* 1990;33:731-4.
29. Anderson BB, Cadogan CA, Gangadharam D. Hidradenitis suppurativa of the perineum, scrotum, and gluteal area: presentation, complications, and treatment. *J Natl Med Assoc* 1982;74:999-1003.
30. Paletta C, Jurkiewicz MJ. Hidradenitis suppurativa. *Clin Plast Surg* 1987;14:383-90.
31. Chaikin DC, Volz LR, Broderick G. An unusual presentation of hidradenitis suppurativa: case report and review of the literature. *Urology* 1994;44:606-8.
32. Yu CC, Cook MG. Hidradenitis suppurativa: a disease of follicular epithelium, rather than apocrine glands. *Br J Dermatol* 1990;122:763-9.
33. Jackman RJ. Hidradenitis suppurativa: diagnosis and surgical management of perianal manifestations. *Proc R Soc Med* 1959;52(suppl):110-2.
34. Jackman RJ, McQuarrie HB. Hidradenitis suppurativa; its confusion with pilonidal disease and anal fistula. *Am J Surg* 1949;77:349-51.
35. Barth JH, Layton AM, Cunliffe WJ. Endocrine factors in pre- and postmenopausal women with hidradenitis suppurativa. *Br J Dermatol* 1996;134:1057-9.
36. Hurlley H. *Dermatologic surgery, principles and practice*. New York: Marcel Dekker; 1989.
37. Jemec GB, Wendelboe P. Topical clindamycin versus systemic tetracycline in the treatment of hidradenitis suppurativa. *J Am Acad Dermatol* 1998;39:971-4.
38. Sartorius K, Lapins J, Emtestam L, Jemec GB. Suggestions for uniform outcome variables when reporting treatment effects in hidradenitis suppurativa. *Br J Dermatol* 2003;149:211-3.
39. Gordon SW. Hidradenitis suppurativa: a closer look. *J Natl Med Assoc* 1978;70:339-43.
40. Schiefferdecker P. *Über morphologische Sekretionserscheinungen in den ekkrinen Hautdrüsen des Menschen*. *Arch Derm Syphilol* 1921;182:130.
41. Shelley WB, Cahn MM. The pathogenesis of hidradenitis suppurativa in man; experimental and histologic observations. *AMA Arch Derm* 1955;72:562-5.
42. Anderson DK, Perry AW. Axillary hidradenitis. *Arch Surg* 1975;110:69-72.
43. Heller DS, Haefner HK, Hameed M, Lieberman RW. Vulvar hidradenitis suppurativa. Immunohistochemical evaluation of apocrine and eccrine involvement. *J Reprod Med* 2002;47:695-700.
44. Morgan WP, Hughes LE. The distribution, size and density of the apocrine glands in hidradenitis suppurativa. *Br J Surg* 1979;66:853-6.
45. Jemec GB, Thomsen BM, Hansen U. The homogeneity of hidradenitis suppurativa lesions. A histological study of intra-individual variation. *APMIS* 1997;105:378-83.
46. Attanoos RL, Appleton MA, Douglas-Jones AG. The pathogenesis of hidradenitis suppurativa: a closer look at apocrine and apoecrine glands. *Br J Dermatol* 1995;133:254-8.
47. Jemec GB, Hansen U. Histology of hidradenitis suppurativa. *J Am Acad Dermatol* 1996;34:994-9.
48. Lapins J, Jarstrand C, Emtestam L. Coagulase-negative staphylococci are the most common bacteria found in cultures from the deep portions of hidradenitis suppurativa lesions, as obtained by carbon dioxide laser surgery. *Br J Dermatol* 1999;140:90-5.
49. Jemec GB, Gniadecka M. Ultrasound examination of hair follicles in hidradenitis suppurativa. *Arch Dermatol* 1997;133:967-70.
50. Kurzen H, Kurokawa I, Jemec GB, Emtestam L, Sellheyer K, Giamarellos-Bourboulis EJ, et al. What causes hidradenitis suppurativa? *Exp Dermatol* 2008;17:455-6.
51. Gniadecki R, Jemec GB. Lipid raft-enriched stem cell-like keratinocytes in the epidermis, hair follicles and sinus tracts in hidradenitis suppurativa. *Exp Dermatol* 2004;13:361-3.
52. Von Der Werth JM, Williams HC, Raeburn JA. The clinical genetics of hidradenitis suppurativa revisited. *Br J Dermatol* 2000;142:947-53.
53. Gao M, Wang PG, Cui Y, Yang S, Zhang YH, Lin D, et al. Inversa acne (hidradenitis suppurativa): a case report and identification of the locus at chromosome 1p21.1-1q25.3. *J Invest Dermatol* 2006;126:1302-6.

54. Barth JH, Kealey T. Androgen metabolism by isolated human axillary apocrine glands in hidradenitis suppurativa. *Br J Dermatol* 1991;125:304-8.
55. Stellon AJ, Wakeling M. Hidradenitis suppurativa associated with use of oral contraceptives. *BMJ* 1989;298:28-9.
56. Jemec GB, Heidenheim M, Nielsen NH. Hidradenitis suppurativa—characteristics and consequences. *Clin Exp Dermatol* 1996;21:419-23.
57. Combleet T. Pregnancy and apocrine gland diseases: hidradenitis, Fox-Fordyce disease. *AMA Arch Derm Syphilol* 1952;65:12-9.
58. Harrison BJ, Kumar S, Read GF, Edwards CA, Scanlon MF, Hughes LE. Hidradenitis suppurativa: evidence for an endocrine abnormality. *Br J Surg* 1985;72:1002-4.
59. Highet AS, Warren RE, Weekes AJ. Bacteriology and antibiotic treatment of perineal suppurative hidradenitis. *Arch Dermatol* 1988;124:1047-51.
60. Leach RD, Eykyn SJ, Phillips I, Corrin B, Taylor EA. Anaerobic axillary abscess. *Br Med J* 1979;2:5-7.
61. Steiner K, Grayson LD. Hidradenitis suppurativa of the adult and its management. *AMA Arch Derm* 1955;71:205-11.
62. Tennant F Jr, Bergeron JR, Stone OJ, Mullins JF. Anemia associated with hidradenitis suppurativa. *Arch Dermatol* 1968;98:138-40.
63. Shaughnessy DM, Greminger RR, Margolis IB, Davis WC. Hidradenitis suppurativa. A plea for early operative treatment. *JAMA* 1972;222:320-1.
64. Bendahan J, Paran H, Kolman S, Neufeld DM, Freund U. The possible role of *Chlamydia trachomatis* in perineal suppurative hidradenitis. *Eur J Surg* 1992;158:213-5.
65. Jemec GB, Faber M, Gutschik E, Wendelboe P. The bacteriology of hidradenitis suppurativa. *Dermatology* 1996;193:203-6.
66. Morgan WP, Leicester G. The role of depilation and deodorants in hidradenitis suppurativa. *Arch Dermatol* 1982;118:101-2.
67. Dvorak VC, Root RK, MacGregor RR. Host-defense mechanisms in hidradenitis suppurativa. *Arch Dermatol* 1977;113:450-3.
68. Lapins J, Asman B, Gustafsson A, Bergstrom K, Emtestam L. Neutrophil-related host response in hidradenitis suppurativa: a pilot study in patients with inactive disease. *Acta Derm Venereol* 2001;81:96-9.
69. Giamarellos-Bourboulis EJ, Antonopoulou A, Petropoulou C, Mouktaroudi M, Spyridaki E, Baziaka F, et al. Altered innate and adaptive immune responses in patients with hidradenitis suppurativa. *Br J Dermatol* 2007;156:51-6.
70. Rosi YL, Lowe L, Kang S. Treatment of hidradenitis suppurativa with infliximab in a patient with Crohn's disease. *J Dermatolog Treat* 2005;16:58-61.
71. Lugerling A, Schmidt M, Lugerling N, Pauels HG, Domschke W, Kucharzik T. Infliximab induces apoptosis in monocytes from patients with chronic active Crohn's disease by using a caspase-dependent pathway. *Gastroenterology* 2001;121:1145-57.
72. Drewe E, McDermott EM, Powell PT, Isaacs JD, Powell RJ. Prospective study of anti-tumour necrosis factor receptor superfamily 1B fusion protein, and case study of anti-tumour necrosis factor receptor superfamily 1A fusion protein, in tumour necrosis factor receptor associated periodic syndrome (TRAPS): clinical and laboratory findings in a series of seven patients. *Rheumatology (Oxford)* 2003;42:235-9.
73. Kastner DL, O'Shea JJ. A fever gene comes in from the cold. *Nat Genet* 2001;29:241-2.
74. Hunger RE, Surovy AM, Hassan AS, Braathen LR, Yawalkar N. Toll-like receptor 2 is highly expressed in lesions of acne inversa and colocalizes with C-type lectin receptor. *Br J Dermatol* 2008;158:691-7.
75. Kim J, Ochoa MT, Krutzik SR, Takeuchi O, Uematsu S, Legaspi AJ, et al. Activation of Toll-like receptor 2 in acne triggers inflammatory cytokine responses. *J Immunol* 2002;169:1535-41.
76. Gupta AK, Knowles SR, Gupta MA, Jaunkalns R, Shear NH. Lithium therapy associated with hidradenitis suppurativa: case report and a review of the dermatologic side effects of lithium. *J Am Acad Dermatol* 1995;32:382-6.
77. Aithal V, Appaih P. Lithium induced hidradenitis suppurativa and acne conglobata. *Indian J Dermatol Venereol Leprol* 2004;70:307-9.
78. Marinella MA. Lithium therapy associated with hidradenitis suppurativa. *Acta Derm Venereol* 1997;77:483.
79. Konig A, Lehmann C, Rompel R, Happle R. Cigarette smoking as a triggering factor of hidradenitis suppurativa. *Dermatology* 1999;198:261-4.
80. Rompel R, Petres J. Long-term results of wide surgical excision in 106 patients with hidradenitis suppurativa. *Dermatol Surg* 2000;26:638-43.
81. Freiman A, Bird G, Metelitsa AI, Barankin B, Lauzon GJ. Cutaneous effects of smoking. *J Cutan Med Surg* 2004;8:415-23.
82. Bassukas ID, Hundeiker M. Acne inversa (pyoderma fistulosum) and smoking. *J Am Acad Dermatol* 1997;36(6 pt 1):1029.
83. Brown SC, Kazzazi N, Lord PH. Surgical treatment of perineal hidradenitis suppurativa with special reference to recognition of the perianal form. *Br J Surg* 1986;73:978-80.
84. von der Werth JM, Jemec GB. Morbidity in patients with hidradenitis suppurativa. *Br J Dermatol* 2001;144:809-13.
85. Wolkenstein P, Loundou A, Barrau K, Auquier P, Revuz J. Quality of life impairment in hidradenitis suppurativa: a study of 61 cases. *J Am Acad Dermatol* 2007;56:621-3.
86. Chicarilli ZN. Follicular occlusion triad: hidradenitis suppurativa, acne conglobata, and dissecting cellulitis of the scalp. *Ann Plast Surg* 1987;18:230-7.
87. Scheinfeld NS. A case of dissecting cellulitis and a review of the literature. *Dermatol Online J* 2003;9:8.
88. Conway H, Stark RB, Climo S, Weeter JC, Garcia FA. The surgical treatment of chronic hidradenitis suppurativa. *Surg Gynecol Obstet* 1952;95:455-64.
89. Hagforsen E, Michaelsson K, Lundgren E, Olofsson H, Petersson A, Lagumdžija A, et al. Women with palmoplantar pustulosis have disturbed calcium homeostasis and a high prevalence of diabetes mellitus and psychiatric disorders: a case-control study. *Acta Derm Venereol* 2005;85:225-32.
90. Gimenez-Garcia R, Sanchez-Ramon S, Cuellar-Olmedo LA. Palmoplantar pustulosis: a clinicoepidemiological study. The relationship between tobacco use and thyroid function. *J Eur Acad Dermatol Venereol* 2003;17:276-9.
91. Maintz L, Betz RC, Allam JP, Wenzel J, Jaksche A, Friedrichs N, et al. Keratitis-ichthyosis-deafness syndrome in association with follicular occlusion triad. *Eur J Dermatol* 2005;15:347-52.
92. Montgomery JR, White TW, Martin BL, Turner ML, Holland SM. A novel connexin 26 gene mutation associated with features of the keratitis-ichthyosis-deafness syndrome and the follicular occlusion triad. *J Am Acad Dermatol* 2004;51:377-82.
93. van Steensel MA, van Geel M, Nahuys M, Smitt JH, Steijlen PM. A novel connexin 26 mutation in a patient diagnosed with keratitis-ichthyosis-deafness syndrome. *J Invest Dermatol* 2002;118:724-7.
94. Richard G, Rouan F, Willoughby CE, Brown N, Chung P, Ryyanen M, et al. Missense mutations in GJB2 encoding

- connexin-26 cause the ectodermal dysplasia keratitis-ichthyosis-deafness syndrome. *Am J Hum Genet* 2002;70:1341-8.
95. Bergeron JR, Stone OJ. Interstitial keratitis associated with hidradenitis suppurativa. *Arch Dermatol* 1967;95:473-5.
  96. Balus L, Fazio M, Amantea A, Menaguale G. Dowling-Degos disease and Verneuil disease [in French]. *Ann Dermatol Venereol* 1993;120:705-8.
  97. Bedlow AJ, Mortimer PS. Dowling-Degos disease associated with hidradenitis suppurativa. *Clin Exp Dermatol* 1996;21:305-6.
  98. Dixit R, George R, Jacob M, Sudarsanam TD, Danda D. Dowling-Degos disease, hidradenitis suppurativa and arthritis in mother and daughter. *Clin Exp Dermatol* 2006;31:454-6.
  99. Fenske NA, Groover CE, Lober CW, Espinoza CG. Dowling-Degos disease, hidradenitis suppurativa, and multiple keratoacanthomas. A disorder that may be caused by a single underlying defect in pilosebaceous epithelial proliferation. *J Am Acad Dermatol* 1991;24:888-92.
  100. Kleeman D, Trueb RM, Schmid-Grendelmeier P. Reticular pigmented anomaly of the flexures. Dowling-Degos disease of the intertrigo type in association with acne inversa [in German]. *Hautarzt* 2001;52:642-5.
  101. Li M, Hunt MJ, Commens CA. Hidradenitis suppurativa, Dowling Degos disease and perianal squamous cell carcinoma. *Australas J Dermatol* 1997;38:209-11.
  102. Loo WJ, Rytina E, Todd PM. Hidradenitis suppurativa, Dowling-Degos and multiple epidermal cysts: a new follicular occlusion triad. *Clin Exp Dermatol* 2004;29:622-4.
  103. Weber LA, Kantor GR, Bergfeld WF. Reticulate pigmented anomaly of the flexures (Dowling-Degos disease): a case report associated with hidradenitis suppurativa and squamous cell carcinoma. *Cutis* 1990;45:446-50.
  104. Bhalla R, Sequeira W. Arthritis associated with hidradenitis suppurativa. *Ann Rheum Dis* 1994;53:64-6.
  105. Ellis BI, Shier CK, Leisen JJ, Kastan DJ, McGoej JW. Acne-associated spondylarthropathy: radiographic features. *Radiology* 1987;162:541-5.
  106. Leybishkis B, Fasseas P, Ryan KF, Roy R. Hidradenitis suppurativa and acne conglobata associated with spondyloarthropathy. *Am J Med Sci* 2001;321:195-7.
  107. Libow LF, Friar DA. Arthropathy associated with cystic acne, hidradenitis suppurativa, and perifolliculitis capitis abscedens et suffodiens: treatment with isotretinoin. *Cutis* 1999;64:87-90.
  108. Rosner IA, Burg CG, Wisnieski JJ, Schacter BZ, Richter DE. The clinical spectrum of the arthropathy associated with hidradenitis suppurativa and acne conglobata. *J Rheumatol* 1993;20:684-7.
  109. Rosner IA, Richter DE, Huettner TL, Kuffner GH, Wisnieski JJ, Burg CG. Spondyloarthropathy associated with hidradenitis suppurative and acne conglobata. *Ann Intern Med* 1982;97:520-5.
  110. Shenefelt PD. Pyoderma gangrenosum associated with cystic acne and hidradenitis suppurativa controlled by adding minocycline and sulfasalazine to the treatment regimen. *Cutis* 1996;57:315-9.
  111. Thein M, Hogarth MB, Acland K. Seronegative arthritis associated with the follicular occlusion triad. *Clin Exp Dermatol* 2004;29:550-2.
  112. Vasey FB, Fenske NA, Clement GB, Bridgford PH, Germain BF, Espinoza LR. Immunological studies of the arthritis of acne conglobata and hidradenitis suppurativa. *Clin Exp Rheumatol* 1984;2:309-11.
  113. Schilling F, Kessler S. SAPHO syndrome: clinico-rheumatologic and radiologic differentiation and classification of a patient sample of 86 cases [in German]. *Z Rheumatol* 2000;59:1-28.
  114. Steinhoff JP, Cilursu A, Falasca GF, Guzman L, Reginato AJ. A study of musculoskeletal manifestations in 12 patients with SAPHO syndrome. *J Clin Rheumatol* 2002;8:13-22.
  115. Kahn MF, Bouvier M, Palazzo E, Tebib JG, Colson F. Sterno-clavicular pustulotic osteitis (SAPHO). 20-year interval between skin and bone lesions. *J Rheumatol* 1991;18:1104-8.
  116. Kahn MF, Chamot AM. SAPHO syndrome. *Rheum Dis Clin North Am* 1992;18:225-46.
  117. Chamot AM, Kahn MF. SAPHO syndrome [in German]. *Z Rheumatol* 1994;53:234-42.
  118. Kahn MF. Current status of the SAPHO syndrome [in French]. *Presse Med* 1995;24:338-40.
  119. Lindor NM, Arsenault TM, Solomon H, Seidman CE, McEvoy MT. A new autosomal dominant disorder of pyogenic sterile arthritis, pyoderma gangrenosum, and acne: PAPA syndrome. *Mayo Clin Proc* 1997;72:611-5.
  120. Church JM, Fazio VW, Lavery IC, Oakley JR, Milsom JW. The differential diagnosis and comorbidity of hidradenitis suppurativa and perianal Crohn's disease. *Int J Colorectal Dis* 1993;8:117-9.
  121. Martinez F, Nos P, Benlloch S, Ponce J. Hidradenitis suppurativa and Crohn's disease: response to treatment with infliximab. *Inflammatory Bowel Dis* 2001;7:323-6.
  122. Burrows NP, Jones RR. Crohn's disease in association with hidradenitis suppurativa. *Br J Dermatol* 1992;126:523.
  123. Todd P, Garioch J, Rademaker M, Susskind W, Gemell C, Thomson J. Pachyonychia congenita complicated by hidradenitis suppurativa: a family study. *Br J Dermatol* 1990;123:663-6.
  124. Leachman SA, Kaspar RL, Fleckman P, Florell SR, Smith FJ, McLean WH, et al. Clinical and pathological features of pachyonychia congenita. *J Invest Dermatol Symp Proc* 2005;10:3-17.
  125. Feinstein A, Friedman J, Schewach-Millet M. Pachyonychia congenita. *J Am Acad Dermatol* 1988;19:705-11.
  126. Moroz A, Lee MH, Clark J. Reflex sympathetic dystrophy with hidradenitis suppurativa exacerbation: a case report. *Arch Phys Med Rehabil* 2001;82:412-4.
  127. Spiller RF, Knox JM. Fox-Fordyce disease with hidradenitis suppurativa. *J Invest Dermatol* 1958;31:127-35.
  128. Maclean GM, Coleman DJ. Three fatal cases of squamous cell carcinoma arising in chronic perineal hidradenitis suppurativa. *Ann R Coll Surg Engl* 2007;89:709-12.
  129. Kurokawa I, Nishimura K, Yamanaka K, Mizutani H, Tsubura A, Revuz J. Cytokeratin expression in squamous cell carcinoma arising from hidradenitis suppurativa (acne inversa). *J Cutan Pathol* 2007;34:675-8.
  130. Maalouf E, Faye O, Poli F, Cosnes A, Revuz J. Fatal epidermoid carcinoma in hidradenitis suppurativa following treatment with infliximab [in French]. *Ann Dermatol Venereol* 2006;133(5 pt 1):473-4.
  131. Talmant JC, Bruant-Rodier C, Nunziata AC, Rodier JF, Wilk A. Squamous cell carcinoma arising in Verneuil's disease: two cases and literature review [in French]. *Ann Chir Plast Esthet* 2006;51:82-6.
  132. Short KA, Kalu G, Mortimer PS, Higgins EM. Vulval squamous cell carcinoma arising in chronic hidradenitis suppurativa. *Clin Exp Dermatol* 2005;30:481-3.
  133. Crain VA, Gulati S, Bhat S, Milner SM. Marjolin's ulcer in chronic hidradenitis suppurativa. *Am Fam Physician* 2005;71(1652):1657.
  134. Rosenzweig LB, Brett AS, Lefavre JF, Vandersteenhoven JJ. Hidradenitis suppurativa complicated by squamous cell

- carcinoma and paraneoplastic neuropathy. *Am J Med Sci* 2005;329:150-2.
135. Bocchini SF, Habr-Gama A, Kiss DR, Imperiale AR, Araujo SE. Gluteal and perianal hidradenitis suppurativa: surgical treatment by wide excision. *Dis Colon Rectum* 2003;46:944-9.
  136. Altunay IK, Gokdemir G, Kurt A, Kayaoglu S. Hidradenitis suppurativa and squamous cell carcinoma. *Dermatol Surg* 2002;28:88-90.
  137. Manolitsas T, Biankin S, Jaworski R, Wain G. Vulval squamous cell carcinoma arising in chronic hidradenitis suppurativa. *Gynecol Oncol* 1999;75:285-8.
  138. Lin MT, Breiner M, Fredricks S. Marjolin's ulcer occurring in hidradenitis suppurativa. *Plast Reconstr Surg* 1999;103:1541-3.
  139. Ritz JP, Runkel N, Haier J, Buhr HJ. Extent of surgery and recurrence rate of hidradenitis suppurativa. *Int J Colorectal Dis* 1998;13:164-8.
  140. Gur E, Neligan PC, Shafir R, Reznick R, Cohen M, Shpitzer T. Squamous cell carcinoma in perineal inflammatory disease. *Ann Plast Surg* 1997;38:653-7.
  141. Malaguarnera M, Pontillo T, Pistone G, Succi L. Squamous-cell cancer in Verneuil's disease (hidradenitis suppurativa). *Lancet* 1996;348:1449.
  142. Dufresne RG Jr, Ratz JL, Bergfeld WF, Roenigk RK. Squamous cell carcinoma arising from the follicular occlusion triad. *J Am Acad Dermatol* 1996;35:475-7.
  143. Shukla VK, Hughes LE. A case of squamous cell carcinoma complicating hidradenitis suppurativa. *Eur J Surg Oncol* 1995;21:106-9.
  144. Perez-Diaz D, Calvo-Serrano M, Martinez-Hijosa E, Fuenmayor-Valera L, Munoz-Jimenez F, Turegano-Fuentes F, et al. Squamous cell carcinoma complicating perianal hidradenitis suppurativa. *Int J Colorectal Dis* 1995;10:225-8.
  145. Welsh DA, Powers JS. Elevated parathyroid hormone-related protein and hypercalcemia in a patient with cutaneous squamous cell carcinoma complicating hidradenitis suppurativa. *South Med J* 1993;86:1403-4.
  146. Mendonca H, Rebelo C, Fernandes A, Lino A, Garcia e Silva L. Squamous cell carcinoma arising in hidradenitis suppurativa. *J Dermatol Surg Oncol* 1991;17:830-2.
  147. Anstey AV, Wilkinson JD, Lord P. Squamous cell carcinoma complicating hidradenitis suppurativa. *Br J Dermatol* 1990;123:527-31.
  148. Brown MD, Zachary CB, Grekin RC, Swanson NA. Genital tumors: their management by micrographic surgery. *J Am Acad Dermatol* 1988;18:115-22.
  149. Zachary LS, Robson MC, Rachmaninoff N. Squamous cell carcinoma occurring in hidradenitis suppurativa. *Ann Plast Surg* 1987;18:71-3.
  150. Sparks MK, Kuhlman DS, Prieto A, Callen JP. Hypercalcemia in association with cutaneous squamous cell carcinoma. Occurrence as a late complication of hidradenitis suppurativa. *Arch Dermatol* 1985;121:243-6.
  151. Camisa C. Squamous cell carcinoma arising in acne conglobata. *Cutis* 1984;33:185-7, 90.
  152. Gordon SW. Squamous cell carcinoma arising in hidradenitis suppurativa: case report. *Plast Reconstr Surg* 1977;60:800-2.
  153. Humphrey LJ, Playforth H, Leavell UW Jr. Squamous cell carcinoma arising in hidradenitis suppurativum. *Arch Dermatol* 1969;100:59-62.
  154. Donsky HJ. Complications of hidradenitis suppurative. *J Dermatol Surg* 1976;2(362):415.
  155. Donsky HJ, Mendelson CG. Squamous cell carcinoma as a complication of hidradenitis suppurativa. *Arch Dermatol* 1964;90:488-91.
  156. Cosman BC, O'Grady TC, Pekarske S. Verrucous carcinoma arising in hidradenitis suppurativa. *Int J Colorectal Dis* 2000;15:342-6.
  157. Lapins J, Ye W, Nyren O, Emtestam L. Incidence of cancer among patients with hidradenitis suppurativa. *Arch Dermatol* 2001;137:730-4.
  158. Konety BR, Cooper T, Flood HD, Futrell JW. Scrotal elephantiasis associated with hidradenitis suppurativa. *Plast Reconstr Surg* 1996;97:1243-5.
  159. Russ E, Castillo M. Lumbosacral epidural abscess due to hidradenitis suppurativa. *AJR Am J Roentgenol* 2002;178:770-1.
  160. Moschella SL. Hidradenitis suppurativa. Complications resulting in death. *JAMA* 1966;198:201-3.
  161. Lee RA, Yoon A, Kist J. Hidradenitis suppurativa: an update. *Adv Dermatol* 2007;23:289-306.
  162. Clemmensen OJ. Topical treatment of hidradenitis suppurativa with clindamycin. *Int J Dermatol* 1983;22:325-8.
  163. Mendonca CO, Griffiths CE. Clindamycin and rifampicin combination therapy for hidradenitis suppurativa. *Br J Dermatol* 2006;154:977-8.
  164. Kaur MR, Lewis HM. Hidradenitis suppurativa treated with dapson: a case series of five patients. *J Dermatolog Treat* 2006;17:211-3.
  165. Boer J, van Gemert MJ. Long-term results of isotretinoin in the treatment of 68 patients with hidradenitis suppurativa. *J Am Acad Dermatol* 1999;40:73-6.
  166. Mortimer PS, Dawber RP, Gales MA, Moore RA. A double-blind controlled cross-over trial of cyproterone acetate in females with hidradenitis suppurativa. *Br J Dermatol* 1986;115:263-8.
  167. Sawers RS, Randall VA, Ebling FJ. Control of hidradenitis suppurativa in women using combined antiandrogen (cyproterone acetate) and oestrogen therapy. *Br J Dermatol* 1986;115:269-74.
  168. Joseph MA, Jayaseelan E, Ganapathi B, Stephen J. Hidradenitis suppurativa treated with finasteride. *J Dermatolog Treat* 2005;16:75-8.
  169. Kraft JN, Searles GE. Hidradenitis suppurativa in 64 female patients: retrospective study comparing oral antibiotics and antiandrogen therapy. *J Cutan Med Surg* 2007;11:125-31.
  170. Bolanowski A, Mannon RB, Holland SM, Malech HL, Aschan J, Palmbld J, et al. Successful renal transplantation in patients with chronic granulomatous disease. *Am J Transplant* 2006;6:636-9.
  171. Buckley DA, Rogers S. Cyclosporin-responsive hidradenitis suppurativa. *J R Soc Med* 1995;88:289P-90P.
  172. Rose RF, Goodfield MJ, Clark SM. Treatment of recalcitrant hidradenitis suppurativa with oral ciclosporin. *Clin Exp Dermatol* 2006;31:154-5.
  173. Tsianos EV, Dalekos GN, Tzermias C, Merkouropoulos M, Hatzis J. Hidradenitis suppurativa in Crohn's disease. A further support to this association. *J Clin Gastroenterol* 1995;20:151-3.
  174. Jemec GB. Methotrexate is of limited value in the treatment of hidradenitis suppurativa. *Clin Exp Dermatol* 2002;27:528-9.
  175. Moschella SL. Is there a role for infliximab in the current therapy of hidradenitis suppurativa? A report of three treated cases. *Int J Dermatol* 2007;46:1287-91.
  176. Mekkes JR, Bos JD. Long-term efficacy of a single course of infliximab in hidradenitis suppurativa. *Br J Dermatol* 2008;158:370-4.
  177. Gheorghe C, Cotruta B, Trifu V, Grasu M, Gheorghe L. QUIZ HQ 40. Perineal abscesses and fistulas—always a mark of Crohn's disease? *J Gastrointest Liver Dis* 2007;16:307-8, 342.

178. Fernandez-Vozmediano JM, Armario-Hita JC. Infliximab for the treatment of hidradenitis suppurativa. *Dermatology* 2007;215:41-4.
179. Pedraz J, Dauden E, Perez-Gala S, Goiriz-Valdes R, Fernandez-Penas P, Garcia-Diez A. Hidradenitis suppurativa. Response to treatment with infliximab [in Spanish]. *Actas Dermosifiliogr* 2007;98:325-31.
180. Usmani N, Clayton TH, Everett S, Goodfield MD. Variable response of hidradenitis suppurativa to infliximab in four patients. *Clin Exp Dermatol* 2007;32:204-5.
181. Fardet L, Dupuy A, Kerob D, Levy A, Allez M, Begon E, et al. Infliximab for severe hidradenitis suppurativa: transient clinical efficacy in 7 consecutive patients. *J Am Acad Dermatol* 2007;56:624-8.
182. Thielen AM, Barde C, Saurat JH. Long-term infliximab for severe hidradenitis suppurativa. *Br J Dermatol* 2006;155:1105-7.
183. Alexis AF, Strober BE. Off-label dermatologic uses of anti-TNF- $\alpha$  therapies. *J Cutan Med Surg* 2005;9:296-302.
184. Cusack C, Buckley C. Etanercept: effective in the management of hidradenitis suppurativa. *Br J Dermatol* 2006;154:726-9.
185. Trent JT, Kerdel FA. Tumor necrosis factor alpha inhibitors for the treatment of dermatologic diseases. *Dermatol Nurs* 2005;17:97-107.
186. Gupta AK, Skinner AR. A review of the use of infliximab to manage cutaneous dermatoses. *J Cutan Med Surg* 2004;8:77-89.
187. Adams DR, Gordon KB, Devenyi AG, Ioffreda MD. Severe hidradenitis suppurativa treated with infliximab infusion. *Arch Dermatol* 2003;139:1540-2.
188. Sullivan TP, Welsh E, Kerdel FA, Burdick AE, Kirsner RS. Infliximab for hidradenitis suppurativa. *Br J Dermatol* 2003;149:1046-9.
189. Lebowitz B, Sapadin AN. Infliximab for the treatment of hidradenitis suppurativa. *J Am Acad Dermatol* 2003;49:S275-6.
190. Katsanos KH, Christodoulou DK, Tsianos EV. Axillary hidradenitis suppurativa successfully treated with infliximab in a Crohn's disease patient. *Am J Gastroenterol* 2002;97:2155-6.
191. Brunasso AM, Delfino C, Massone C. Hidradenitis suppurativa: are tumour necrosis factor- $\alpha$  blockers the ultimate alternative? *Br J Dermatol* 2008;159:761-3.
192. Zangrilli A, Esposito M, Mio G, Mazzotta A, Chimenti S. Long-term efficacy of etanercept in hidradenitis suppurativa. *J Eur Acad Dermatol Venereol* 2008;22:1260-2.
193. Moul DK, Korman NJ. The cutting edge. Severe hidradenitis suppurativa treated with adalimumab. *Arch Dermatol* 2006;142:1110-2.
194. Scheinfeld N. Treatment of coincident seronegative arthritis and hidradenitis suppurativa with adalimumab. *J Am Acad Dermatol* 2006;55:163-4.
195. Bongartz T, Sutton AJ, Sweeting MJ, Buchan I, Matteson EL, Montori V. Anti-TNF antibody therapy in rheumatoid arthritis and the risk of serious infections and malignancies: systematic review and meta-analysis of rare harmful effects in randomized controlled trials. *JAMA* 2006;295:2275-85.
196. Menter A, Gottlieb A, Feldman SR, Van Voorhees AS, Leonardi CL, Gordon KB, et al. Guidelines of care for the management of psoriasis and psoriatic arthritis: section 1. Overview of psoriasis and guidelines of care for the treatment of psoriasis with biologics. *J Am Acad Dermatol* 2008;58:826-50.
197. Wallis RS, Broder MS, Wong JY, Hanson ME, Beenhouwer DO. Granulomatous infectious diseases associated with tumor necrosis factor antagonists. *Clin Infect Dis* 2004;38:1261-5.
198. Slifman NR, Gershon SK, Lee JH, Edwards ET, Braun MM. *Listeria monocytogenes* infection as a complication of treatment with tumor necrosis factor alpha-neutralizing agents. *Arthritis Rheum* 2003;48:319-24.
199. Lee JH, Slifman NR, Gershon SK, Edwards ET, Schwieterman WD, Siegel JN, et al. Life-threatening histoplasmosis complicating immunotherapy with tumor necrosis factor alpha antagonists infliximab and etanercept. *Arthritis Rheum* 2002;46:2565-70.
200. Brocard A, Knol AC, Khammari A, Dreno B. Hidradenitis suppurativa and zinc: a new therapeutic approach. A pilot study. *Dermatology* 2007;214:325-7.
201. Norris C. Hidradenitis and response to oral steroids. *Br J Dermatol* 1987;117(suppl 32):96-7.
202. Treatment of hidradenitis suppurativa. *JAMA* 1973;223:556-7.
203. Kipping HF. How I treat hidradenitis suppurativa. *Postgrad Med J* 1970;48:291-2.
204. Camisa C, Sexton C, Friedman C. Treatment of hidradenitis suppurativa with combination hypothalamic-pituitary-ovarian and adrenal suppression. A case report. *J Reprod Med* 1989;34:543-6.
205. Danto JL. Preliminary studies of the effect of hydrocortisone on hidradenitis suppurativa. *J Invest Dermatol* 1958;31:299-300.
206. O'Reilly DJ, Pleat JM, Richards AM. Treatment of hidradenitis suppurativa with botulinum toxin A. *Plast Reconstr Surg* 2005;116:1575-6.
207. Zeligman I. Temporary x-ray epilation therapy of chronic axillary hidradenitis suppurativa. *Arch Dermatol* 1965;92:690-4.
208. Schenck SG. Hidradenitis suppurativa axillaris; an analysis of 54 cases treated with roentgen rays. *Radiology* 1950;54:74-7.
209. Pape R, Golles D. Effect of roentgen microdosage in axillar hidrosadenitis [in German]. *Strahlentherapie* 1950;81:565-76.
210. Frohlich D, Baaske D, Glatzel M. Radiotherapy of hidradenitis suppurativa—still valid today? [in German]. *Strahlenther Onkol* 2000;176:286-9.
211. Pedraz J, Dauden E. Practical management of hidradenitis suppurativa [in Spanish]. *Actas Dermosifiliogr* 2008;99:101-10.
212. Bong JL, Shalders K, Saihan E. Treatment of persistent painful nodules of hidradenitis suppurativa with cryotherapy. *Clin Exp Dermatol* 2003;28:241-4.
213. Dalrymple JC, Monaghan JM. Treatment of hidradenitis suppurativa with the carbon dioxide laser. *Br J Surg* 1987;74:420.
214. Lapins J, Sartorius K, Emtestam L. Scanner-assisted carbon dioxide laser surgery: a retrospective follow-up study of patients with hidradenitis suppurativa. *J Am Acad Dermatol* 2002;47:280-5.
215. Sherman AI, Reid R. CO<sub>2</sub> laser for suppurative hidradenitis of the vulva. *J Reprod Med* 1991;36:113-7.
216. Wasaki J, Marra DE, Fincher EF, Moy RL. Treatment of hidradenitis suppurativa with a nonablative radiofrequency device. *Dermatol Surg* 2008;34:114-7.
217. Gold M, Bridges TM, Bradshaw VL, Boring M. ALA-PDT and blue light therapy for hidradenitis suppurativa. *J Drugs Dermatol* 2004;3:S32-5.
218. Rivard J, Ozog D. Henry Ford Hospital dermatology experience with Levulan Kerastick and blue light photodynamic therapy. *J Drugs Dermatol* 2006;5:556-61.

219. Strauss RM, Pollock B, Stables GI, Goulden V, Cunliffe WJ. Photodynamic therapy using aminolaevulinic acid does not lead to clinical improvement in hidradenitis suppurativa. *Br J Dermatol* 2005;152:803-4.
220. Harrison BJ, Mudge M, Hughes LE. Recurrence after surgical treatment of hidradenitis suppurativa. *Br Med J (Clin Res Ed)* 1987;294:487-9.
221. Watson JD. Hidradenitis suppurativa—a clinical review. *Br J Plast Surg* 1985;38:567-9.
222. Mandal A, Watson J. Experience with different treatment modules in hidradenitis suppurativa: a study of 106 cases. *Surgeon* 2005;3:23-6.
223. Morgan WP, Harding KG, Hughes LE. A comparison of skin grafting and healing by granulation, following axillary excision for hidradenitis suppurativa. *Ann R Coll Surg Engl* 1983;65:235-6.
224. Jemec GBE, Revuz J, Leyden JJ. *Hidradenitis suppurativa*. Berlin-Heidelberg-New York: Springer-Verlag; 2006.