

REVIEW ARTICLE

Hereditary palmoplantar keratoderma “clinical and genetic differential diagnosis”

Tomo SAKIYAMA, Akiharu KUBO

Department of Dermatology, Keio University School of Medicine, Tokyo, Japan

ABSTRACT

Hereditary palmoplantar keratoderma (PPK) is a heterogeneous group of disorders characterized by hyperkeratosis of the palm and the sole skin. Hereditary PPK are divided into four groups – diffuse, focal, striate and punctate PPK – according to the clinical patterns of the hyperkeratotic lesions. Each group includes simple PPK, without associated features, and PPK with associated features, such as involvement of nails, teeth and other organs. PPK have been classified by a clinically based descriptive system. In recent years, many causative genes of PPK have been identified, which has confirmed and/or rearranged the traditional classifications. It is now important to diagnose PPK by a combination of the traditional morphological classification and genetic testing. In this review, we focus on PPK without associated features and introduce their morphological features, genetic backgrounds and new findings from the last decade.

Key words: diffuse, focal, punctate, striate, transgrediens.

INTRODUCTION

Palmoplantar keratoderma (PPK) is a heritable or acquired disorder characterized by abnormal hyperkeratotic thickening of the palm and sole skin. In a narrow sense, PPK implies hereditary PPK, the phenotype of which usually appears at an early age. Hereditary PPK are divided into two categories: PPK without associated features and PPK with associated features, such as lesions of the non-volar skin, nails, hair, teeth and involvement of other organs. Clinical diagnosis of PPK is sometimes difficult because of genetic heterogeneity, clinical heterogeneity and the probable existence of as yet unidentified PPK. Genetic heterogeneity means phenotypic similarities among several PPK caused by mutations in different genes, and clinical heterogeneity means distinct phenotypes caused by different mutations of the same genes. Because most of the causative genes have been identified in hereditary PPK within the last two decades, genetic testing is indispensable for the diagnosis of PPK, in combination with clinical-based morphological classifications.

DIFFERENTIAL DIAGNOSIS OF PPK

In the clinic, acquired PPK are important in the differential diagnoses of hereditary PPK, especially for hereditary PPK without associated features. Acquired PPK usually occur later in life and may be due to many causes, such as keratoderma climactericum, drugs, malnutrition, chemicals, systemic disease, malignancy, dermatoses, infections and idiopathies.¹ For example, acquired PPK due to contact dermatitis (Fig. 1a) and

psoriasis vulgaris confined to the palmoplantar area (Fig. 1b) are comparatively common and are sometimes difficult to distinguish from hereditary PPK. A skin biopsy is essential in diagnosing these cases. Lack of a family history is not necessarily evidence of an acquired PPK, because autosomal recessive PPK can appear sporadically from parent carriers and because autosomal dominant PPK can also occur sporadically by *de novo* mutations.

Careful observations, history taking, skin biopsy and genetic testing are important in diagnosing hereditary PPK. Hereditary PPK are divided morphologically into four types – diffuse, focal, striate and punctate – according to the mode and distribution of hyperkeratosis. This review is intended to provide an overview of the distinctive clinical phenotypes of hereditary PPK, especially PPK without associated features, and introduces recent progress in our understanding of their molecular pathogenesis. A list of known subtypes of PPK without associated features is shown in Table 1 for the diffuse type and in Table 2 for other types.

DIFFUSE PPK WITHOUT TRANSGREDIENS

Diffuse PPK shows diffuse hyperkeratosis over the palms and soles. One of the key points for a clinical diagnosis is the presence or absence of transgrediens, an expansion of the disease phenotype to the dorsal surfaces of the hands and feet, inner wrists and the Achilles tendon area. Diffuse PPK without transgrediens include Vörner PPK (Mendelian Inheritance in Man [MIM] no. 144200) and diffuse PPK caused by heterozygous distinct mutation of *DSG1* (MIM no. 148700).^{2,3} Both are

Correspondence: Akiharu Kubo, M.D., Ph.D., Department of Dermatology, Keio University School of Medicine, 35 Shinanomachi, Shinjuku-ku, Tokyo 160-8582, Japan. Email: akiharu@a5.keio.jp

Received 13 October 2015; accepted 15 October 2015.

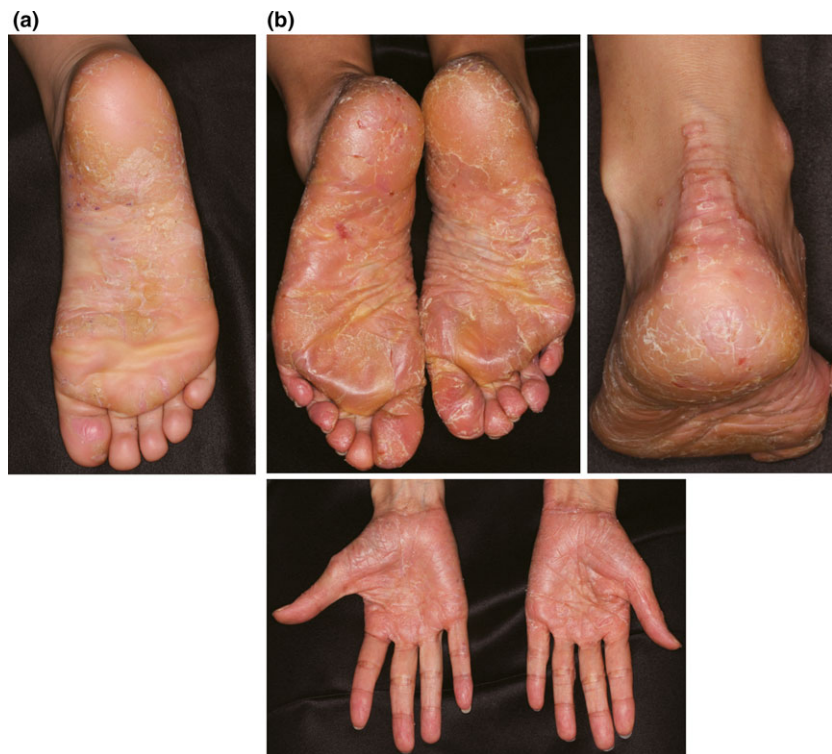

Figure 1. Acquired palmoplantar keratoderma (PPK) (a) Acquired PPK due to contact dermatitis. (b) Acquired PPK due to psoriasis vulgaris.

autosomal dominant traits but can be distinguished by histological findings and the responsible genes. Vörner PPK is diffuse PPK (Fig. 2) caused by mutations in *KRT1* or *KRT9* and histologically shows epidermolytic hyperkeratosis.^{2,4–6} Unna–Thost PPK (MIM no. 600962) was recognized as a non-epidermolytic form of diffuse PPK that resembles Vörner PPK clinically. However, Küster *et al.*⁷ investigated the offspring of the original family diagnosed by Unna and Thost and found epidermolytic hyperkeratosis by histology. Genetic testing revealed the p.R162W mutation in *KRT9* in the original family evaluated by Unna and Thost and the p.N160I mutation in *KRT9* in the original family evaluated by Vörner, and both mutations are located on the coil-1A segment at the beginning of the central rod domain of *KRT9*.^{5,6} Thus, it seems likely that Unna–Thost PPK and Vörner PPK are the same entity.

Diffuse PPK caused by *DSG1* mutations show enlarged intercellular spaces and partial separation of keratinocytes in spinous and granular cell layers on histology.^{3,8} Mutations in *DSG1* show clinical heterogeneity; striate PPK, diffuse PPK, focal PPK and SAM syndrome, described below, are all caused by different mutations of *DSG1*.^{3,9–11}

DIFFUSE PPK WITH TRANSGREDIENS

Diffuse PPK with transgrediens include several diseases: mal de Meleda (MIM no. 248300), acral keratoderma, and PPK of Nagashima (MIM no. 615598), Bothnian (MIM no. 600231), Gamborg-Nielsen (MIM no. 244850), Greither (MIM no. 144200), and Sybert.^{12–20} Among these, Nagashima PPK

and Bothnian PPK are specifically characterized by a whitish spongy change in palmoplantar hyperkeratotic skin upon water exposure.^{16,21}

Nagashima PPK shows autosomal recessive behavior and is the most common PPK in Japan and China, estimated at 1.2/10 000 and 3.1/10 000, respectively, according to a cohort study.²¹ Nagashima PPK was first described as a PPK showing a similar distribution to, but a considerably milder disease phenotype than, mal de Meleda by Masaji Nagashima in the Japanese published work in 1977.²² Mal de Meleda is the most severe and progressive hyperkeratosis among the diffuse PPK and leads to constricting bands, spontaneous amputation and/or flexion contractures (Fig. 3).¹² Nagashima PPK shows a non-progressive, mild hyperkeratosis with skin redness and does not show constricting bands, spontaneous amputation or flexion contractures (Fig. 4a).^{14,15} In 2013, Kubo *et al.* identified, by whole-exome sequencing, biallelic loss-of-function mutations in *SERPINB7*, which encodes a cytoplasmic member of the serine protease inhibitor superfamily, as a cause of Nagashima PPK,²¹ confirming that Nagashima PPK is genetically distinct from mal de Meleda, which is caused by biallelic mutations in *SLURP1*.²³ The whitish spongy change upon water exposure in Nagashima PPK has been suggested to result from enhanced water permeation into the stratum corneum, damaged by overactivated proteases due to the lack of *SERPINB7* (Fig. 4b).²¹

Bothnian PPK was first described in 1994 as an autosomal dominant form of diffuse non-epidermolytic PPK, which has a high prevalence of 0.3–0.55% in the two northernmost

Table 1. Classification of diffuse PPK

| | Mode of inheritance | Causative genes | Pathological findings | Manifestation of PPK | Transgrediens | Hyperhidrosis | Whitish change upon water exposure | Development on other areas | Spontaneous amputation |
|--|---------------------|---|---|--|---------------|---------------|------------------------------------|--|------------------------|
| Vörner ² (Unna-Thost) Diffuse PPK with <i>DSG1</i> mutations ³ | AD | <i>KRT1</i> ⁴ <i>KRT9</i> ^{5,6} <i>DSG1</i> | Epidermolytic hyperkeratosis Enlarged intercellular spaces and partial separation of keratinocytes | Thick hyperkeratosis Thick hyperkeratosis | - | - | - | - | - |
| Nagashima ^{14,15} | AR | <i>SERPINB7</i> ²¹ | Non-epidermolytic hyperkeratosis | Mild hyperkeratosis with redness | + | + | + | Knees, elbows, and Achilles tendon area | - |
| Bothnian ¹⁶ | AD | <i>AQP5</i> ²⁴ | Non-epidermolytic hyperkeratosis | Mild to thick hyperkeratosis | + | + | + | - | - |
| Greither ¹⁹ | AD | <i>KRT7</i> ²⁷ | Non-epidermolytic hyperkeratosis | Thick hyperkeratosis | + | + | - | Elbows, knees, flexural areas, and Achilles tendon | + |
| Sybert ²⁰ | AD | Unknown | Non-epidermolytic hyperkeratosis | Thick hyperkeratosis | + | Not described | - | Natal cleft, groin, elbows, knees, posterior aspects of forearms, and anterior aspects of legs | + |
| Mal de Meleda ¹² | AR | <i>SLURP1</i> ²³ | Non-epidermolytic hyperkeratosis | Severe hyperkeratosis | + | + | - | Knees and elbows, perioral erythema, and periorbital erythema | Occasionally |
| Gamborg Nielsen ^{17,18} | AR | <i>SLURP1</i> ²⁶ | Non-epidermolytic hyperkeratosis | Thick hyperkeratosis | + | Not described | + | Only knuckle pads on the dorsa of the fingers | Not described |
| Acral keratoderma ¹³ | AR | Unknown | Non-epidermolytic hyperkeratosis | Thick diffuse and striate hyperkeratosis | + | Not described | - | Linear hyperkeratotic lesions over knees, elbows, ankles, and Achilles tendon area | + |

AD, autosomal dominant inheritance, AR, autosomal recessive inheritance; PPK, palmo/plantar keratoderma.

Table 2. Classification of focal, striate and punctate PPK

| Type of PPK | Mode of inheritance | Responsible gene | Characteristic clinical manifestation |
|---|---------------------|--|--|
| Focal | AD | <i>KRT16</i> , ^{33,34} <i>KRT6c</i> , ³⁵ <i>DSG1</i> , ⁹ <i>TRPV3</i> , ³⁶ | Circumscribed calluses on the palms and soles with slight or no nail lesions. The lesion can be painful and induced by mechanical stress |
| Striate | AD | <i>DSG1</i> ¹⁰ | Skin thickening is prominent in a linear pattern along the flexor aspects of the fingers and over pressure points on the soles. Types I–III are classified by the responsible gene |
| Punctate | AD | <i>DSP</i> ³⁸ | Multiple tiny punctate keratosis on the palms and soles appear during late childhood to adolescence and increase in number with age to form larger lesions. Type IA and IB are classified by the responsible genes |
| | AD | <i>KRT1</i> ²⁸ | |
| | AD | <i>AAGAB</i> ^{45,46} | |
| Punctate (Buschke–Fischer–Brauer type) ^{41,42} | AD | <i>COL14A1</i> ⁴⁷ | |
| Punctate PPK type IB | AD | Unknown | Tiny keratotic spines on the palms and soles begin during the early 20s. Histological examination reveals columnar parakeratosis |
| Punctate PPK type II (porokeratotic type) ⁴³ | AD | Unknown | Small keratotic papules which mainly involve the margins of the hands and feet appear in adolescence or adult life. Histological examination reveals degeneration of elastic fibers |
| Punctate PPK type III (acrokeratolastoidosis) ⁴⁴ | AD | Unknown | |

AD, autosomal dominant inheritance; AR, autosomal recessive inheritance; PPK, palmoplantar keratoderma.

provinces of Sweden, situated to the west and northwest of the Gulf of Bothnia.¹⁶ Bothnian PPK resembles Nagashima PPK in terms of its mild hyperkeratosis with transgrediens and the whitish spongy changes upon water exposure (Fig. 5).¹⁶ In 2013, Blaydon *et al.*²⁴ identified heterozygous missense mutations in *AQP5*, encoding water-channel protein AQP5, in affected members of seven Swedish families, three British families and one Scottish family. It was suggested from protein modeling that the amino acid substitution found in Bothnian PPK may increase the diameter of the constriction point of the water channel of AQP5.²⁴ Thus, the Bothnian PPK sequence variants could have a direct influence on AQP5 gating and/or water flow through the channel.²⁴

Whitish spongy changes in the palms are also observed in other disease conditions, such as aquagenic wrinkling of the palms,²⁵ a rare condition characterized by excessive wrinkling, palmar edema and whitish papules after brief exposure to water (Fig. 6). This condition has been reported mostly in patients and carriers for cystic fibrosis (MIM no. 219700), caused by mutations of *CFTR*.²⁵ There are several hypotheses as to the disease mechanism of aquagenic wrinkling of the palms, including dysfunction of the TRPV4 channel in the keratinocytes of cystic fibrosis patients that results in dysregulated water influx through eccrine ducts.²⁵

Gamborg-Nielsen PPK shows a similar morphological phenotype to mal de Meleda but has been reported to have less severe hyperkeratosis and no nail deformities or distant keratosis, except for the knuckle pads. Thus, the two disorders have been considered to be independent diseases.^{17,18} In 2014, Zhao *et al.*²⁶ performed genetic analysis of 15 individuals with Gamborg-Nielsen PPK from nine families. Of these, 14 were described previously by Gamborg-Nielsen *et al.* and were born in the northernmost counties of Sweden.^{18,26} They found a homozygous mutation, c.43T>C, of *SLURP1* in 14 individuals from the northernmost counties of Sweden and a compound heterozygous mutation, c.280T>A and c.43T>C, of *SLURP1* in one individual from southern Sweden. Because the c.43T>C mutation had been reported in mal de Meleda, Gamborg-Nielsen PPK is considered an allelic variant of mal de Meleda.²⁶ The individual with the compound heterozygous mutation of c.280T>A and c.43T>C in *SLURP1* showed whitish spongy changes upon water exposure, typically not observed in Gamborg-Nielsen PPK or mal de Meleda.²⁶

Greither PPK and Sybert PPK are both autosomal dominant forms of diffuse PPK with transgrediens and progressive features with age.^{19,20} Sybert PPK shows more severe and a wider range of hyperkeratosis than does Greither PPK.²⁰ Greither PPK is caused by a *KRT1* mutation – Greither PPK, Vörner PPK, striate PPK, epidermolytic hyperkeratosis (MIM no. 113800), ichthyosis histrix (MIM no. 146590) and cyclic ichthyosis with epidermolytic hyperkeratosis (MIM no. 607602) show clinical heterogeneity of *KRT1* mutations – but the gene locus for Sybert PPK is unknown.^{4,27–31} Acral keratoderma is an autosomal recessive PPK and shows a characteristic morphology and distribution of hyperkeratosis: diffuse and striate hyperkeratosis of the palms and soles and linear hyperkeratotic lesions over the elbows, knees and Achilles tendon area.¹³

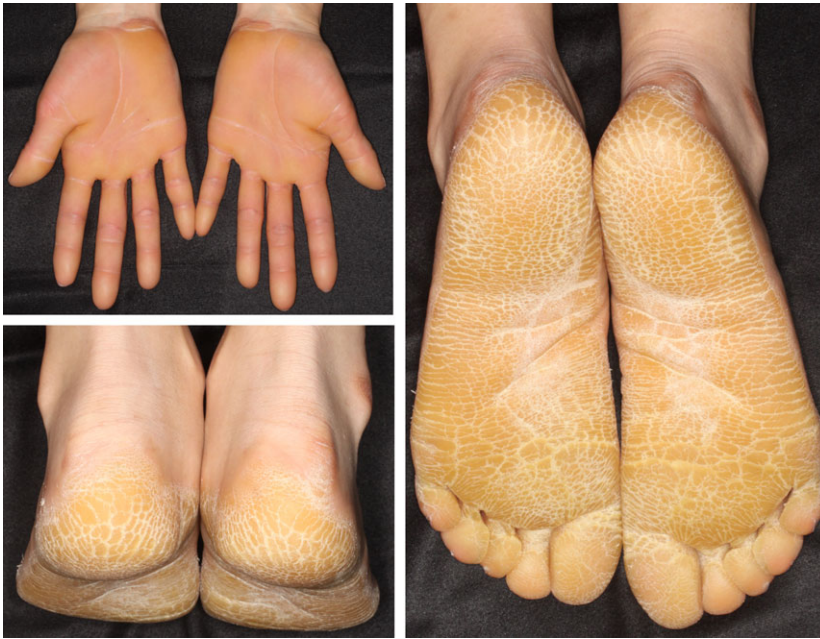

Figure 2. Vörner palmoplantar keratoderma (PPK) showing diffuse hyperkeratosis without transgrediens.

FOCAL PPK

Painful circumscribed hyperkeratosis, like calluses, on the bodyweight-loading area of the soles is characteristic of focal PPK (Fig. 7a). Focal PPK is known for its major symptom of pachyonychia congenita (MIM no. 167200, 167210, 615726, 615728), caused by heterozygous mutations of *KRT6A*, *KRT6B*, *KRT16* or *KRT17*.³² While hypertrophic nail dystrophy and several ectodermal features are complicated in pachyonychia congenita patients, specific mutations in *KRT16* (MIM no. 613000) cause focal PPK with or without minimal changes in the nails and other ectodermal tissues.^{33,34} Mutations in *KRT6C* (MIM no. 615735) and a specific mutation in *DSG1* (MIM no. 148700) also cause focal PPK with or without minimal changes in the nails and other ectodermal tissues.^{9,35}

In 2015, a gain-of-function mutation in *TRPV3* was identified as the cause of focal PPK (MIM no. 616400) in a Chinese family by whole-genome sequencing.³⁶ *TRPV3* belongs to a large family of calcium-permeable transient receptor potential ion channel membrane proteins, and the mutation in *TRPV3* was suggested to disrupt the balance between keratinocyte proliferation and differentiation.³⁶ Several mutations in *TRPV3* have also been reported as the cause of Olmsted syndrome (MIM no. 614594), which shows mutilating diffuse PPK and perioral hyperkeratotic plaques, supporting the importance of *TRPV3* activity in keratinocyte differentiation.^{36,37}

STRIATE PPK

Striate PPK shows skin thickening, which is prominent in a linear pattern along the flexor aspects of the fingers and over pressure points on the soles (Fig. 7b). It shows autosomal dominant inheritance and is divided into three types according

to the responsible gene: *DSG1* (MIM no. 148700), *DSP* (MIM no. 612908) and *KRT1* (MIM no. 607654).^{10,28,38}

Heterozygous mutations in *DSG1* cause striate, diffuse and focal PPK.^{3,9,10} *DSG1* is a major component of desmosomes in the upper layer of the epidermis, and loss of *DSG1* expression on the cell membrane leads to weakened intercellular adhesion. Thus, histopathological features of PPK with *DSG1* mutations show characteristic clues of varying degrees of intercellular space enlargement and partial separation of keratinocytes in the spinous and granular cell layers.⁸

In 2013, Samuelov *et al.*¹¹ reported that patients who had homozygous *DSG1* mutations causing striate PPK via consanguineous marriage revealed a new syndrome, comprising severe dermatitis, multiple allergies and metabolic wasting (SAM) syndrome (MIM no. 615508). The clinical manifestations were congenital ichthyosiform erythroderma, focal and striate PPK, and hypotrichosis. They had multiple food allergies, elevated immunoglobulin E levels and recurrent infections with malabsorption. Regarding the pathoetiology, the lack of membrane expression of *DSG1* may result in a compromised epidermal barrier, resulting in sensitization to multiple environmental allergens. SAM syndrome belongs to a group of diseases, including Netherton syndrome (MIM no. 256500) and peeling skin syndrome caused by corneodesmosin deficiency (MIM no. 270300), in which congenital insufficiency of the stratum corneum barrier causes erythroderma and multiple allergies. Recently, milder cases of SAM syndrome were also reported with PPK, dermatitis and multiple allergies but without hypotrichosis, metabolic wasting and severe recurrent infection.^{39,40}

PUNCTATE PPK

Punctate PPK is clinically classified into three groups: Buschke–Fischer–Brauer type (MIM no. 148600, 614936),

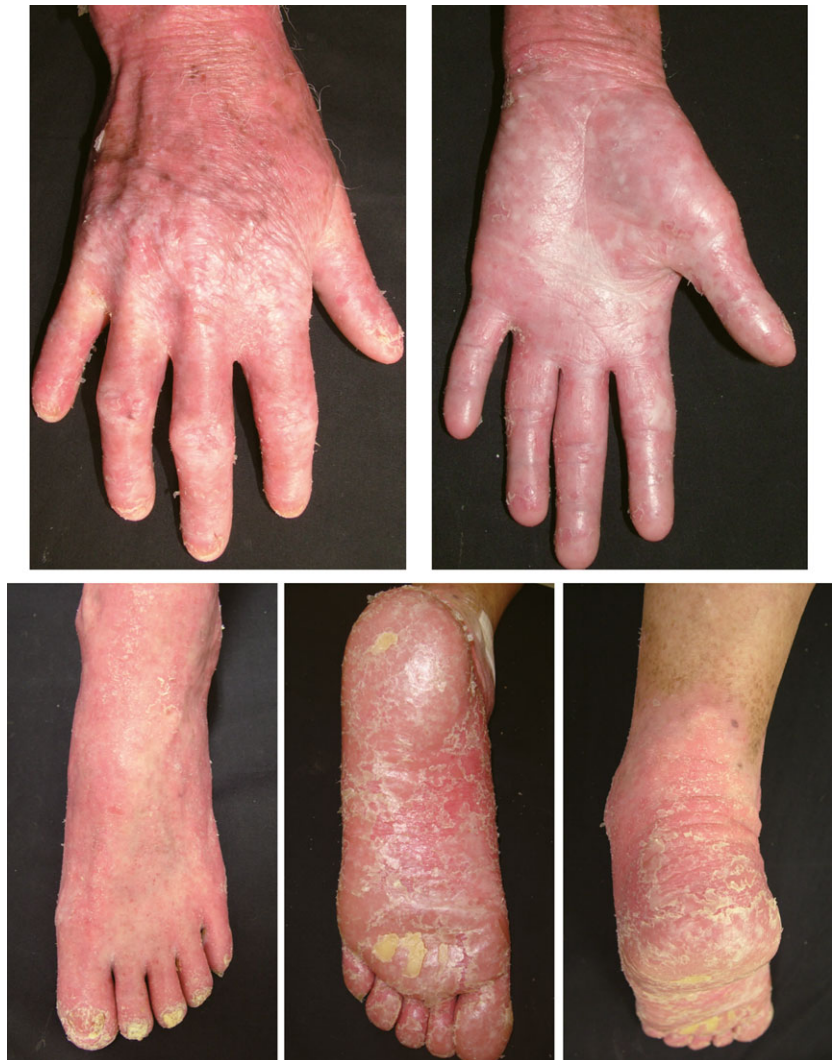

Figure 3. Mal de Meleda showing the most severe hyperkeratosis with transgrediens and leading to flexion contractures. (Photos kindly provided by Dr Yoshiki Tokura.)⁵⁹

porokeratotic type (MIM no. 175860) and acrokeratoelastoidosis (MIM no. 101850).^{41–44} All show autosomal dominant inheritance, whereas the clinical manifestations of each are different and characteristic. Buschke–Fischer–Brauer type PPK shows multiple tiny punctate keratoses on the palms and soles (Fig. 7c).^{41,42} It appears during late childhood to adolescence, and the lesions increase in number with advancing age and form larger lesions. Heterozygous mutations in *AAGAB*, encoding α - and γ -adaptin-binding protein p34, and *COL14A1*, were identified as causes of Buschke–Fischer–Brauer PPK.^{45–47} Porokeratotic-type PPK shows tiny keratotic spines on the palms and soles, beginning during an individual's early 20s, and histological examination reveals columnar parakeratosis.⁴³ Acrokeratoelastoidosis is characterized by small keratotic papules that primarily involve the margins of the hands and feet, appearing during adolescence or adult life, and histological findings reveal degeneration of elastic fibers.⁴⁴ The gene(s) responsible for porokeratotic-type PPK and acrokeratoelastoidosis remain unknown.

DIAGNOSTIC APPROACH TO HEREDITARY PPK

To diagnose hereditary PPK without associated features, first, we should examine the involvement of other skin areas, such as nails, hair, teeth and other organs, to exclude PPK with associated features. There are many PPK with associated features and we introduce several of them below.

- 1 Huriez syndrome (MIM no. 181600), the causative gene of which is still unknown, shows diffuse and transgradient PPK, scleroatrophy of the distal extremities, nail changes, growth delays affecting the hands and increased risk of squamous cell carcinoma.⁴⁸
- 2 Mutations in *GJB2*, encoding connexin 26, cause PPK with neurosensory deafness (MIM no. 148350), KID syndrome (MIM no. 148210), HID syndrome (MIM no. 602540), Bart–Pumphrey syndrome (MIM no. 149200) and Vohwinkel syndrome (MIM no. 124500), all of which show sensorineural deafness and diffuse PPK with transgrediens.^{48–50} KID

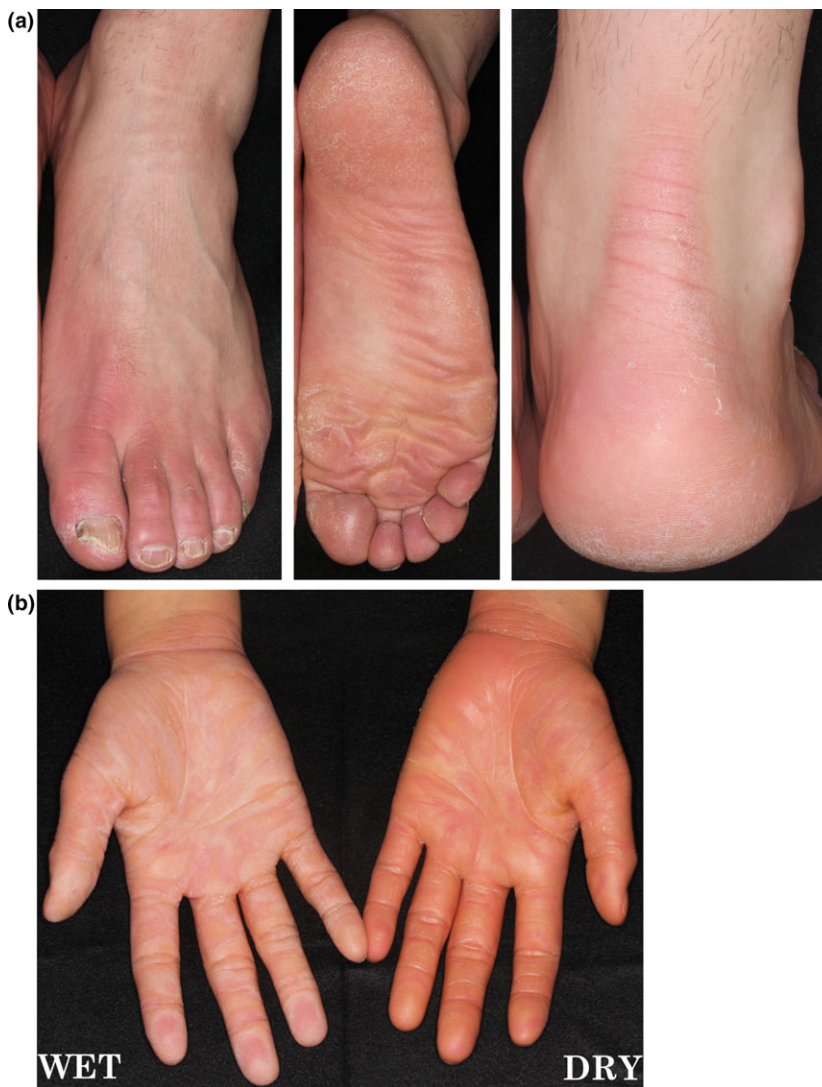

Figure 4. (a) Nagashima palmoplantar keratoderma (PPK) showing mild hyperkeratosis with skin redness and transgrediens. (b) Right hand showing whitish spongy changes after 5 min water exposure.

syndrome is a diffuse PPK associated with ichthyosiform erythroderma in infants, progressive verruciform hyperkeratosis, recurrent infections and increased risk of squamous cell carcinoma.⁴⁸ Bart–Pumphrey syndrome shows knuckle pads and leukonychia.⁴⁸ Vohwinkel syndrome shows mutilating PPK, characterized by constriction ring formation with alopecia and nail dystrophy.⁴⁸ A variant form of Vohwinkel syndrome with ichthyosis (MIM no. 604117) is caused by mutations in *LOR*, which is sometimes called lorcin keratoderma.⁴⁸

- 3 Clouston syndrome (MIM no. 129500), caused by mutations in *GJB6* encoding connexin 30, shows moderate to severe PPK with dystrophy of the nails and defects of the hair.^{51,52}
- 4 Olmsted syndrome – the autosomal dominant form (MIM no. 614594) is caused by mutations in *TRPV3*³⁷ and the X-linked form (MIM no. 300918) caused by a mutation in *MBTPS2*⁴⁸ – shows diffuse and mutilating PPK and perioral hyperkeratotic plaques with severe pruritus. Diffuse alope-

cia, constriction of the digits, onychodystrophy and squamous cell carcinomas arising in the keratotic areas have also been reported.

- 5 Naegeli–Franceschetti–Jadassohn syndrome (MIM no. 161000), caused by mutations in *KRT14*, shows diffuse PPK, the absence of papillary relief, nail dystrophies, anhidrosis, dental defects, and hyperpigmentation and loss of pigmentation.⁴⁸
- 6 Papillon–Lefèvre syndrome (MIM no. 245000), caused by mutations in *CTSC* encoding cathepsin C, shows diffuse and transgradient PPK, periodontitis leading to tooth loss, and recurrent cutaneous and systemic infections.⁴⁸
- Haim–Munk syndrome (MIM no. 245010) is also caused by mutations in *CTSC* and resembles Papillon–Lefèvre syndrome, but is complicated by arachnodactyly, acroosteolysis, pes planus and finger deformities.⁴⁸
- 7 KLiCK syndrome (MIM no. 601952), caused by mutations in *POMP*, shows diffuse, transgressive PPK with linear hyperkeratotic plaques and congenital ichthyosis.⁴⁸

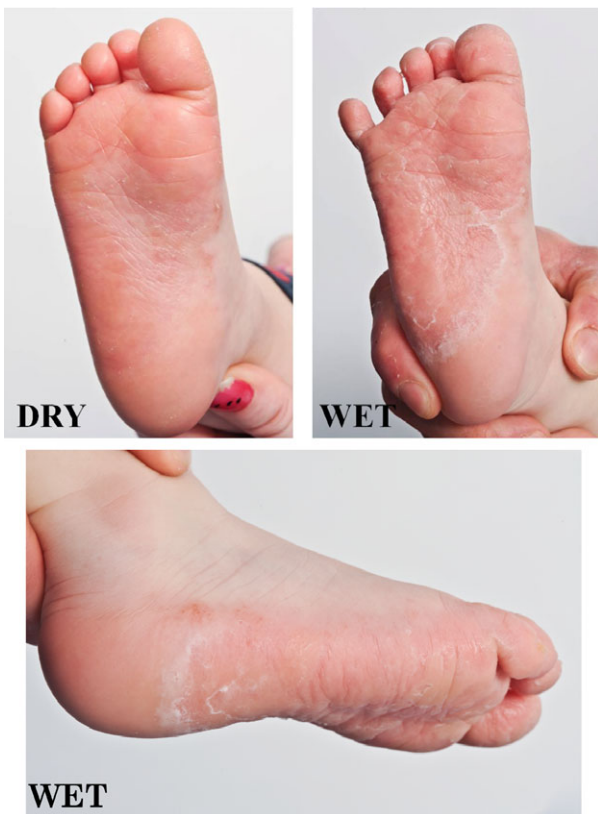

Figure 5. Bothnian palmoplantar keratoderma (PPK) resembles Nagashima PPK in showing mild hyperkeratosis with transgrediens and whitish spongy changes upon water exposure. (Photos kindly provided by Dr John McGrath).⁶⁰

- 8 Odontoonychodermal dysplasia (MIM no. 257980), caused by mutations in *WNT10A*, is an autosomal recessive ectodermal dysplasia characterized by diffuse PPK, hypodontia, hypertrichosis and dystrophic nails.⁴⁸
- 9 Schöpf-Schulz-Passarge syndrome (MIM no. 224750), caused by mutations in *WNT10A*, resembles odontoonychodermal dysplasia, but is complicated by cysts affecting the eyelids and an increased risk of skin tumors.⁴⁸
- 10 Pachyonychia congenita, caused by mutations in *KRT6A*, *KRT6B*, *KRT16* or *KRT17*, shows focal or diffuse PPK, hypertrophic nail dystrophy and oral leukokeratosis, sometimes with a variety of epidermal cysts.³²
- 11 Tylosis with esophageal cancer (MIM no. 148500), caused by mutations in *RHBDF2*, is characterized by focal PPK, esophageal cancer and oral precursor lesions, such as leukoplakia.⁵³
- 12 Mutations in the genes encoding desmosomal plaque proteins cause striate PPK with associated features. Carvajal syndrome (MIM no. 605676), caused by mutations in *DSP*, encoding desmoplakin, shows striate PPK with cardiomyopathy and woolly hair.⁴⁸ In some cases, tooth agenesis is a complication (MIM no. 615821).⁵⁴ Naxos disease (MIM no. 601214), caused by mutations in *JUP*, encoding plakoglobin, shows diffuse PPK, cardiomyopathy and woolly hair.⁴⁸ Both skin fragility syndrome (MIM no. 604536), caused by mutations in *PKP1*, and skin fragility

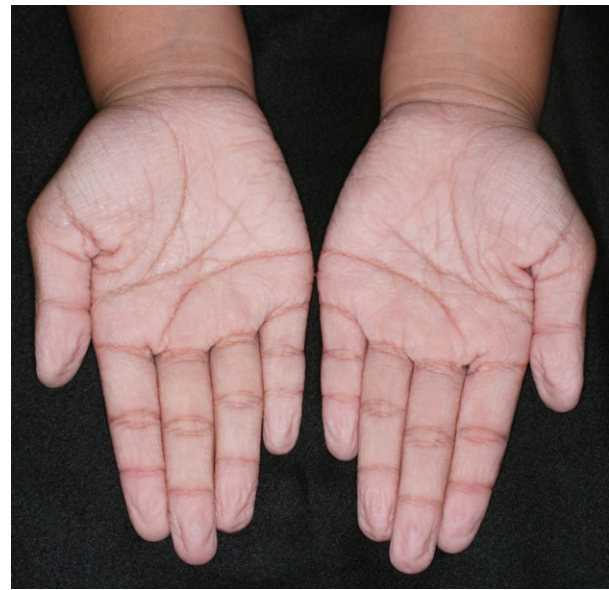


Figure 6. Aquagenic wrinkling of the palms, showing excessive wrinkling, palmar edema and whitish papules after brief exposure to water.

woolly hair syndrome (MIM no. 607655), caused by mutations in *DSP*, show PPK.^{55,56}

- 13 Epidermolysis bullosa simplex with mottled pigmentation (MIM no. 131960), caused by a specific p.P25L mutation in *KRT5*, shows punctate PPK with mottled pigmentation on the skin, especially of the limbs. Localized skin blistering and fragility have been observed, mostly during childhood.^{57,58}

CONCLUSIONS AND FUTURE PERSPECTIVES

In the clinical diagnosis of PPK, we should pay attention to the nails and hair disorders, intraoral conditions, other skin manifestations, hearing acuity, and past and/or family history of recurrent infection and squamous cell carcinoma to distinguish PPK with or without associated features. Morphological features and the distribution of hyperkeratinization (i.e. diffuse, focal, striate and punctate patterns) are helpful in the differential diagnosis. In the case of diffuse PPK, the presence/absence of transgrediens and whitish change upon water exposure are also helpful in narrowing down the differential diagnosis. Genetic testing should be performed to confirm the clinical diagnosis, which is especially helpful for identifying PPK with associated features for the prevention of recurrent infections and the development of squamous cell carcinoma.

There are still uncharacterized hereditary PPK. When genetic testing fails to detect causative mutations and when clinical manifestations are distinct from known PPK, whole-exome sequencing can be used to detect novel causative gene(s) of a novel type of PPK. In the hunt for new causative genes, it is important to recruit individuals who have mutations in the same causative gene and therefore show the identical phenotype, so phenotypic classifica-

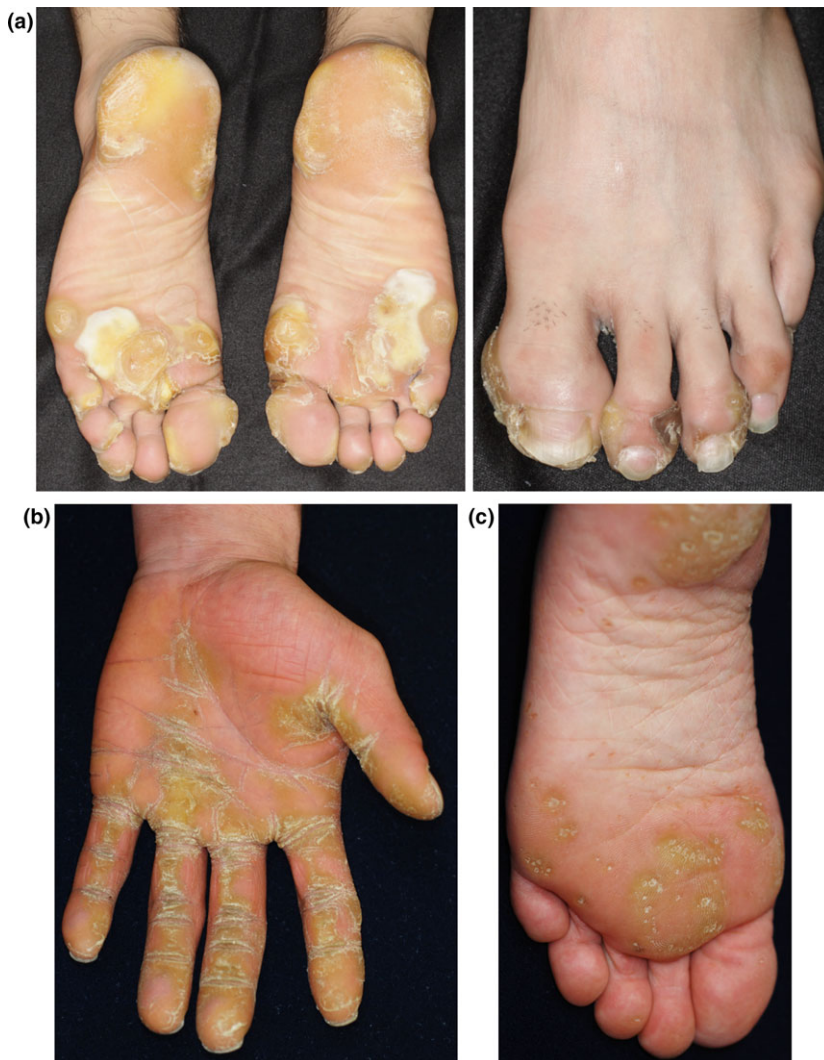

Figure 7. (a) Focal palmoplantar keratoderma (PPK), caused by a *KRT6C* mutation, showing painful circumscribed hyperkeratosis, such as calluses on the bodyweight-loading area of the soles.⁶¹ (b) Striate PPK, caused by a *DSG1* mutation, showing skin thickening, with a prominent linear pattern along the flexor aspects of the fingers. (Photos kindly provided by Dr Toshifumi Nomura.)⁶² (c) Buschke-Fischer-Brauer PPK, caused by an *AAGAB* mutation, showing multiple tiny punctate keratoses on the palms and soles. (Photos kindly provided by Dr Toshifumi Nomura.)⁶³

tions by clinicians and the development of a network to find rare and undiagnosed PPK patients will become even more important.

ACKNOWLEDGMENT: This work is partly supported by Japan Agency for Medical Research and Development.

CONFLICT OF INTEREST: None declared.

REFERENCES

- 1 Patel S, Zirwas M, English JC 3rd. Acquired palmoplantar keratoderma. *Am J Clin Dermatol* 2007; **8**: 1–11.
- 2 Vörner H. Zur Kenntnis des Keratoma hereditarium palmare et plantare. *Arch Dermatol Syph* 1901; **56**: 3–31.
- 3 Keren H, Bergman R, Mizrahi M *et al.* Diffuse nonepidermolytic palmoplantar keratoderma caused by a recurrent nonsense mutation in *DSG1*. *Arch Dermatol* 2005; **141**: 625–628.

- 4 Hatsell SJ, Eady RA, Wennerstrand L *et al.* Novel splice site mutation in keratin 1 underlies mild epidermolytic palmoplantar keratoderma in three kindreds. *J Invest Dermatol* 2001; **116**: 606–609.
- 5 Reis A, Hennies HC, Langbein L *et al.* Keratin 9 gene mutations in epidermolytic palmoplantar keratoderma (EPPK). *Nat Genet* 1994; **6**: 174–179.
- 6 Küster W, Reis A, Hennies HC. Epidermolytic palmoplantar keratoderma of Vorner: re-evaluation of Vorner's original family and identification of a novel keratin 9 mutation. *Arch Dermatol Res* 2002; **294**: 268–272.
- 7 Küster W, Becker A. Indication for the identity of palmoplantar keratoderma type Unna-Thost with type Vorner. Thost's family revisited 110 years later. *Acta Derm Venereol* 1992; **72**: 120–122.
- 8 Bergman R, Hershkovitz D, Fuchs D *et al.* Disadhesion of epidermal keratinocytes: a histologic clue to palmoplantar keratodermas caused by *DSG1* mutations. *J Am Acad Dermatol* 2010; **62**: 107–113.
- 9 Milingou M, Wood P, Masouye I *et al.* Focal palmoplantar keratoderma caused by an autosomal dominant inherited mutation in the desmoglein 1 gene. *Dermatology* 2006; **212**: 117–122.
- 10 Rickman L, Simrak D, Stevens HP *et al.* N-terminal deletion in a desmosomal cadherin causes the autosomal dominant skin disease

- striate palmoplantar keratoderma. *Hum Mol Genet* 1999; **8**: 971–976.
- 11 Samuelov L, Sarig O, Harmon RM *et al.* Desmoglein 1 deficiency results in severe dermatitis, multiple allergies and metabolic wasting. *Nat Genet* 2013; **45**: 1244–1248.
 - 12 Hovorka O, Ehlers E. Mal de Meleda. *Arch Dermatol Res* 1897; **40**: 251–256.
 - 13 Nesbitt LT Jr, Rothschild H, Ichinose H *et al.* Acral keratoderma. *Arch Dermatol* 1975; **111**: 763–768.
 - 14 Mitsuhashi Y, Hashimoto I. Keratosis palmoplantaris Nagashima. *Dermatologica* 1989; **179**: 231.
 - 15 Kabashima K, Sakabe J, Yamada Y *et al.* “Nagashima-type” keratosis as a novel entity in the palmoplantar keratoderma category. *Arch Dermatol* 2008; **144**: 375–379.
 - 16 Lind L, Lundstrom A, Hofer PA *et al.* The gene for diffuse palmoplantar keratoderma of the type found in northern Sweden is localized to chromosome 12q11–q13. *Hum Mol Genet* 1994; **3**: 1789–1793.
 - 17 Gamborg Nielsen P. Two different clinical and genetic forms of hereditary palmoplantar keratoderma in the northernmost county of Sweden. *Clin Genet* 1985; **28**: 361–366.
 - 18 Kastl I, Anton-Lamprecht I, Gamborg Nielsen P. Hereditary palmoplantar keratosis of the Gamborg Nielsen type. Clinical and ultrastructural characteristics of a new type of autosomal recessive palmoplantar keratosis. *Arch Dermatol Res* 1990; **282**: 363–370.
 - 19 Greither A. Keratosis extrematum hereditaria progrediens mit dominantem Erbgang. *Hautarzt* 1952; **3**: 198–203.
 - 20 Sybert VP, Dale BA, Holbrook KA. Palmar-plantar keratoderma. A clinical, ultrastructural, and biochemical study. *J Am Acad Dermatol* 1988; **18**: 75–86.
 - 21 Kubo A, Shiohama A, Sasaki T *et al.* Mutations in SERPINB7, encoding a member of the serine protease inhibitor superfamily, cause Nagashima-type palmoplantar keratosis. *Am J Hum Genet* 2013; **93**: 945–956.
 - 22 Nagashima M. *Palmoplantar Keratoses*. In *Handbook of Human Genetics*, Volume 9. Tokyo: Igaku Shoin, 1977.
 - 23 Fischer J, Bouadjar B, Heilig R *et al.* Mutations in the gene encoding SLURP-1 in Mal de Meleda. *Hum Mol Genet* 2001; **10**: 875–880.
 - 24 Blaydon DC, Lind LK, Plagnol V *et al.* Mutations in AQP5, encoding a water-channel protein, cause autosomal-dominant diffuse nonepidermolytic palmoplantar keratoderma. *Am J Hum Genet* 2013; **93**: 330–335.
 - 25 Park L, Khani C, Tamburro J. Aquagenic wrinkling of the palms and the potential role for genetic testing. *Pediatr Dermatol* 2012; **29**: 237–242.
 - 26 Zhao L, Vahlquist A, Virtanen M *et al.* Palmoplantar keratoderma of the Gamborg-Nielsen type is caused by mutations in the SLURP1 gene and represents a variant of Mal de Meleda. *Acta Derm Venereol* 2014; **94**: 707–710.
 - 27 Gach JE, Munro CS, Lane EB *et al.* Two families with Greither’s syndrome caused by a keratin 1 mutation. *J Am Acad Dermatol* 2005; **53**: S225–S230.
 - 28 Whittock NV, Smith FJ, Wan H *et al.* Frameshift mutation in the V2 domain of human keratin 1 results in striate palmoplantar keratoderma. *J Invest Dermatol* 2002; **118**: 838–844.
 - 29 Rothnagel JA, Dominey AM, Dempsey LD *et al.* Mutations in the rod domains of keratins 1 and 10 in epidermolytic hyperkeratosis. *Science* 1992; **257**: 1128–1130.
 - 30 Sprecher E, Ishida-Yamamoto A, Becker OM *et al.* Evidence for novel functions of the keratin tail emerging from a mutation causing ichthyosis hystrix. *J Invest Dermatol* 2001; **116**: 511–519.
 - 31 Sybert VP, Francis JS, Corden LD *et al.* Cyclic ichthyosis with epidermolytic hyperkeratosis: a phenotype conferred by mutations in the 2B domain of keratin K1. *Am J Hum Genet* 1999; **64**: 732–738.
 - 32 Eliason MJ, Leachman SA, Feng BJ *et al.* A review of the clinical phenotype of 254 patients with genetically confirmed pachyonychia congenita. *J Am Acad Dermatol* 2012; **67**: 680–686.
 - 33 Shamsher MK, Navsaria HA, Stevens HP *et al.* Novel mutations in keratin 16 gene underlying focal non-epidermolytic palmoplantar keratoderma (NEPPK) in two families. *Hum Mol Genet* 1995; **4**: 1875–1881.
 - 34 Smith FJ, Fisher MP, Healy E *et al.* Novel keratin 16 mutations and protein expression studies in pachyonychia congenita type 1 and focal palmoplantar keratoderma. *Exp Dermatol* 2000; **9**: 170–177.
 - 35 Wilson NJ, Messenger AG, Leachman SA *et al.* Keratin K6c mutations cause focal palmoplantar keratoderma. *J Invest Dermatol* 2010; **130**: 425–429.
 - 36 He Y, Zeng K, Zhang X *et al.* A gain-of-function mutation in TRPV3 causes focal palmoplantar keratoderma in a Chinese family. *J Invest Dermatol* 2015; **135**: 907–909.
 - 37 Lin Z, Chen Q, Lee M *et al.* Exome sequencing reveals mutations in TRPV3 as a cause of Olmsted syndrome. *Am J Hum Genet* 2012; **90**: 558–564.
 - 38 Armstrong DK, McKenna KE, Purkis PE *et al.* Haploinsufficiency of desmoplakin causes a striate subtype of palmoplantar keratoderma. *Hum Mol Genet* 1999; **8**: 143–148.
 - 39 Has C, Jakob T, He Y *et al.* Loss of desmoglein 1 associated with palmoplantar keratoderma, dermatitis and multiple allergies. *Br J Dermatol* 2015; **172**: 257–261.
 - 40 Schlipf NA, Vahlquist A, Teigen N *et al.* Whole exome sequencing identifies novel autosomal recessive DSG1 mutations associated with mild SAM syndrome. *Br J Dermatol* 2015; doi: 10.1111/bjd.14079.
 - 41 Buschke A, Fischer W. Keratoderma maculosa disseminate symmetrica palmaris and plantaris. *Ikonographia Dermatol* 1910; **51**: 183–192.
 - 42 Brauer A. Über eine besondere Form des hereditären Keratoms (keratoderma disseminatum hereditarium palmare et plantare). *Arch Dermatol Syph* 1913; **114**: 211–236.
 - 43 Brown FC. Punctate keratoderma. *Arch Dermatol* 1971; **104**: 682–683.
 - 44 Costa O. Akrokerato-elastoidosis (a hitherto undescribed skin disease). *Dermatologica* 1953; **107**: 164–168.
 - 45 Giehl KA, Eckstein GN, Pasternack SM *et al.* Nonsense mutations in AAGAB cause punctate palmoplantar keratoderma type Buschke-Fischer-Brauer. *Am J Hum Genet* 2012; **91**: 754–759.
 - 46 Pohler E, Mamai O, Hirst J *et al.* Haploinsufficiency for AAGAB causes clinically heterogeneous forms of punctate palmoplantar keratoderma. *Nat Genet* 2012; **44**: 1272–1276.
 - 47 Guo BR, Zhang X, Chen G *et al.* Exome sequencing identifies a COL14A1 mutation in a large Chinese pedigree with punctate palmoplantar keratoderma. *J Med Genet* 2012; **49**: 563–568.
 - 48 Schiller S, Seebode C, Hennies HC *et al.* Palmoplantar keratoderma (PPK): acquired and genetic causes of a not so rare disease. *J Dtsch Dermatol Ges* 2014; **12**: 781–788.
 - 49 Heathcote K, Syrris P, Carter ND *et al.* A connexin 26 mutation causes a syndrome of sensorineural hearing loss and palmoplantar hyperkeratosis (MIM 148350). *J Med Genet* 2000; **37**: 50–51.
 - 50 van Geel M, van Steensel MA, Kuster W *et al.* HID and KID syndromes are associated with the same connexin 26 mutation. *Br J Dermatol* 2002; **146**: 938–942.
 - 51 Clouston HR. A hereditary ectodermal dystrophy. *Can Med Assoc J* 1929; **21**: 18–31.
 - 52 Lamartine J, Munhoz Esserfelder G, Kibar Z *et al.* Mutations in GJB6 cause hidrotic ectodermal dysplasia. *Nat Genet* 2000; **26**: 142–144.
 - 53 Blaydon DC, Etheridge SL, Risk JM *et al.* RHBDF2 mutations are associated with tylosis, a familial esophageal cancer syndrome. *Am J Hum Genet* 2012; **90**: 340–346.
 - 54 Norgett EE, Lucke TW, Bowers B *et al.* Early death from cardiomyopathy in a family with autosomal dominant striate palmoplantar keratoderma and woolly hair associated with a novel insertion mutation in desmoplakin. *J Invest Dermatol* 2006; **126**: 1651–1654.
 - 55 McGrath JA, McMillan JR, Shemanko CS *et al.* Mutations in the plakophilin 1 gene result in ectodermal dysplasia/skin fragility syndrome. *Nat Genet* 1997; **17**: 240–244.

- 56 Whittock NV, Wan H, Morley SM *et al.* Compound heterozygosity for non-sense and mis-sense mutations in desmoplakin underlies skin fragility/woolly hair syndrome. *J Invest Dermatol* 2002; **118**: 232–238.
- 57 Uttam J, Hutton E, Coulombe PA *et al.* The genetic basis of epidermolysis bullosa simplex with mottled pigmentation. *Proc Natl Acad Sci USA* 1996; **93**: 9079–9084.
- 58 Glasz-Bona A, Medvecz M, Viragh Z *et al.* Epidermolysis bullosa simplex with mottled pigmentation – mutation analysis proved the diagnosis in a four-generation pedigree. *Eur J Dermatol* 2010; **20**: 698–700.
- 59 Sakabe J, Kabashima-Kubo R, Kubo A *et al.* A Japanese case of Mal de Meleda with SLURP1 mutation. *J Dermatol* 2014; **41**: 764–765.
- 60 Abdul-Wahab A, Takeichi T, Liu L *et al.* Autosomal dominant diffuse non-epidermolytic palmoplantar keratoderma due to a recurrent mutation in aquaporin-5. *Br J Dermatol* 2015; doi: 10.1111/bjd.13931.
- 61 Kubo A, Oura Y, Hirano T *et al.* Collapse of the keratin filament network through the expression of mutant keratin 6c observed in a case of focal plantar keratoderma. *J Dermatol* 2013; **40**: 553–557.
- 62 Nomura T, Mizuno O, Miyauchi T *et al.* Striate palmoplantar keratoderma: report of a novel DSG1 mutation and atypical clinical manifestations. *J Dermatol Sci* 2015; pii: S0923-1811(15)30056-6. doi: 10.1016/j.jdermsci.2015.10.004.
- 63 Nomura T, Moriuchi R, Takeda M *et al.* Low-dose etretinate shows promise in management of punctate palmoplantar keratoderma type 1: case report and review of the published work. *J Dermatol* 2015; **42**: 889–892.