

REVIEW ARTICLE

Dan L. Longo, M.D., *Editor*

Porphyria

D. Montgomery Bissell, M.D., Karl E. Anderson, M.D.,
and Herbert L. Bonkovsky, M.D.

From the Department of Medicine, Division of Gastroenterology and Porphyria Center, University of California, San Francisco, San Francisco (D.M.B.); the Departments of Preventive Medicine and Community Health and Internal Medicine, Division of Gastroenterology and Hepatology, University of Texas Medical Branch, Galveston (K.E.A.); and the Department of Gastroenterology, Wake Forest School of Medicine, Winston-Salem, NC (H.L.B.). Address reprint requests to Dr. Bissell at the University of California, 513 Parnassus Ave., Box 0538, San Francisco, CA 94143, or at montgomery.bissell@ucsf.edu.

N Engl J Med 2017;377:862-72.

DOI: 10.1056/NEJMra1608634

Copyright © 2017 Massachusetts Medical Society.

WHO REMEMBERS PORPHYRIA? FOR MOST HEALTH CARE PROVIDERS, the name encompasses a group of diseases that were mentioned in a lecture and were too rare to commit to memory. However, the prevalence of some types of porphyria may be higher than is generally assumed. In this review, we discuss progress toward understanding the pathogenesis and treatment of these conditions.

The porphyrias are disorders of heme synthesis, which has eight steps (Fig. 1). Each type of porphyria involves a defect, either inherited or acquired, in a pathway enzyme. When the defect is physiologically significant, it results in overproduction of pathway precursors preceding the defective step which enter the circulation and are excreted into urine or bile. The diseases have been grouped as acute hepatic porphyrias and photocutaneous porphyrias. The acute porphyrias are due to hepatic overproduction of the porphyrin precursors, delta aminolevulinic acid and porphobilinogen, and the symptoms are caused by injury primarily to the nervous system. Cutaneous porphyria is due to overproduction of photosensitizing porphyrins by the liver or bone marrow, depending on the type of porphyria.

Acute intermittent porphyria is the acute type most often encountered in clinical practice.^{1,2} The most prevalent cutaneous porphyrias are porphyria cutanea tarda and protoporphyria (Table 1). Hereditary coproporphyria and variegate porphyria are acute forms in which attacks are much less frequent than in acute intermittent porphyria, but photocutaneous disease (similar to porphyria cutanea tarda) can occur. Acute flares are managed as they are in acute intermittent porphyria. Delta aminolevulinic acid dehydratase deficiency and uroporphyrinogen-III synthase deficiency (in congenital erythropoietic porphyria)^{3,4} are very rare and will not be discussed.

ACUTE INTERMITTENT PORPHYRIA

Acute intermittent porphyria is due to partial deficiency of the third enzyme of heme synthesis, porphobilinogen deaminase (or hydroxymethylbilane synthase). It is an autosomal dominant condition that occurs globally. The prevalence of mutations in Western populations is approximately 1 carrier per 2000 persons.^{5,6} However, acute attacks occur in less than 10% of the at-risk population; this reflects a key role of environmental factors and possibly genetic modifiers.^{7,8}

MANIFESTATIONS

The typical patient with an attack of acute intermittent porphyria is a previously healthy young woman who has had several days of severe fatigue and an inability to concentrate,⁹ followed by progressively worsening abdominal pain, nausea, vomiting, and subtle neurologic signs (weakness, dysesthesia, and altered affect).

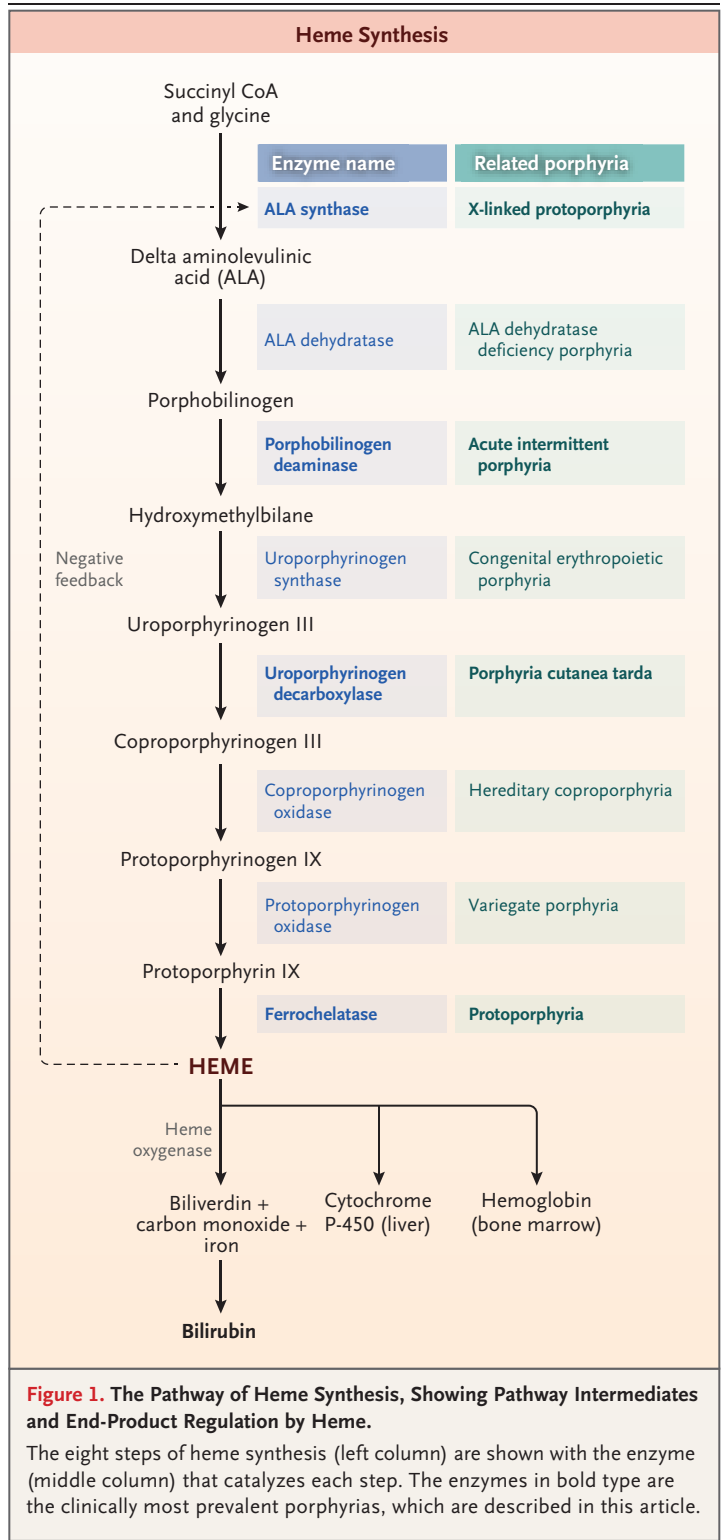
Analgesic agents, including opioids, have provided little or no relief. The patient's medical record may reveal previous visits to the emergency department with the same symptoms and a nondiagnostic evaluation.¹⁰ The vital signs are notable for tachycardia and elevated systolic blood pressure. The abdominal examination is unexpectedly benign. Abdominal imaging may show changes consistent with ileus but otherwise is normal. The lack of objective findings and a poor response to analgesics often create an initial impression of psychosomatic pain or drug addiction.

The laboratory evaluation is normal apart from a minor elevation of liver-enzyme levels and a low serum sodium level. The serum sodium level may decrease precipitously after administration of intravenous glucose in water.¹¹ Although the term porphyria implies purplish urine, the color of freshly voided urine in patients with acute intermittent porphyria may be unremarkable, because the heme precursors for this type, mainly delta aminolevulinic acid and porphobilinogen, are colorless. Voided urine, exposed to light at ambient temperature, will slowly turn dark through formation of uroporphyrin-like pigments (porphobilin). Seizures occur in approximately 20% of acute attacks.¹² The triad of seizures, abdominal pain, and hyponatremia in a young woman is highly suggestive of acute porphyria.

Acute attacks largely occur (in 80 to 90% of cases) in women of reproductive age.¹³ They are unusual before menarche and after menopause. In some cases, they are catamenial, related to the surge in progesterone that occurs between ovulation and the onset of menstruation. Certain medications, including oral contraceptives, may trigger attacks. Acute attacks also occur with caloric deprivation related to intercurrent illness, perisurgical fasting, a crash diet, or bariatric surgery.^{14,15}

DIAGNOSIS

Elevated porphobilinogen levels in urine or plasma are specific for acute porphyria. During an acute flare, the increase is not subtle, reaching 10 to 150 times the upper limit of the normal range (Table 2). The test can be performed in a random sample with the result normalized per gram of urine creatinine; a 24-hour collection is not required. Urinary porphobilinogen is not part of a "porphyrin screen," which measures porphy-



rin levels only. The latter are relevant to cutaneous porphyrias but not to acute intermittent porphyria.

Table 1. Principal Types of Porphyria in the United States and Europe.

Feature	Acute Intermittent Porphyria	Porphyria Cutanea Tarda	Protoporphyrria
Tissue site	Liver	Liver	Bone marrow
Manifestations	Pain in the abdomen and back and nausea, both of which increase over a few days; tachycardia without fever; seizures (in 20% of patients)	Slow onset of painless blisters, fragile skin, scars, hypertrichosis on sun-exposed skin	Rapid onset of pain, edema, and itching after sun exposure; thickening of perioral skin and skin over the knuckles with repeated exposure
Age at onset and sex	18–45 yr; 90% female predominance	>40 yr; male predominance	1–3 yr (although delayed diagnosis is common); equal male–female incidence
Color of urine	Normal to dark amber	Brown or reddish brown	Normal
Associated conditions, environmental factors	Use of cytochrome P-450–inducing medications or oral contraceptive pills, severely restricted caloric intake	Hepatitis C virus infection, human immunodeficiency virus infection, iron overload, use of alcohol, use of estrogen	History of gallstones, microcytic anemia, cholestasis
Skin lesions	None	Painless blisters on sun-exposed skin, shallow open sores, depigmented scars	Acute injury: erythema and mild edema; chronic injury: lichenified skin over knuckles and around mouth

Table 2. Heme Pathway Intermediates in the Diagnosis of Porphyria.*

Pathway Intermediate	Reference Range	Asymptomatic Acute Intermittent Porphyria	Acute Intermittent Porphyria during Attack	Porphyria Cutanea Tarda without Symptoms (Treated)	Active (Untreated) Porphyria Cutanea Tarda	Protoporphyrria
Porphobilinogen in urine (mg/g of creatinine)	0–2	1–10 [†]	20–300	<2	<4	—
Uroporphyrin in urine (μg/g of creatinine)	0–30	<30	20–200	30–300	>500	—
Protoporphyrin in blood (μg/dl)	0–80	—	—	—	—	>400

* To convert the values for porphobilinogen to micromoles per day, divide by 0.226. To convert the values for uroporphyrin to nanomoles per day, divide by 0.831. To convert the values for blood protoporphyrin to nanomoles per deciliter, divide by 0.563.

[†] In a minority of asymptomatic carriers, the level of urine porphobilinogen is higher than 10 mg per gram of creatinine. The risk of an attack is increased, relative to the risk when the baseline porphobilinogen level is normal or only slightly elevated.⁸

Patients with first attacks of acute intermittent porphyria often present to an emergency department, where rare diseases generally are not considered and, moreover, a test to detect porphobilinogen in urine is rarely available in real time. Until the 1990s, rapid methods for measuring porphobilinogen in urine — the Watson–Schwartz test and other tests — were available in many emergency departments. Although these tests were helpful in experienced hands, they were qualitative only and subject to false positive results.

Today, the only route to a confirmed diagnosis is a routine quantitative porphobilinogen test,

which has a turnaround time of 4 to 10 days at commercial reference laboratories. This often means a substantial delay in diagnosis, which can be costly in terms of misdirected medical care, progressive neurologic loss, respiratory paralysis, and even death. One analysis has suggested that an expedited porphobilinogen test for patients in the emergency department would be cost-effective.¹⁶

PATHOGENESIS OF SYMPTOMS

Two hypotheses dominate thinking on the pathogenesis of symptoms in acute intermittent porphyria. One theory envisions cellular heme defi-

ciency leading to a critical reduction in heme proteins in neuronal cells. The second theory postulates that delta aminolevulinic acid is neurotoxic at the levels reached in acute porphyria. The latter idea has support from experimental models.¹⁷⁻¹⁹ In addition, the symptoms of two conditions — tyrosinemia and lead poisoning — resemble those of acute intermittent porphyria, and the delta aminolevulinic acid (but not porphobilinogen) level is elevated in urine in patients with these two conditions.²⁰ The liver has been confirmed as the source of excess delta aminolevulinic acid in porphyria, because patients who undergo liver transplantation for intractable symptoms are cured.²¹

TREATMENT

Initial management includes review of the patient’s medications for any that are considered to be risky in patients with porphyria (Table 3) and the administration of fluids (preferably 10% dextrose in 0.45% saline), antiemetic agents, analgesic agents, and, if indicated, antiseizure medication. For a patient with seizures, the treatment plan must take into account that several commonly used medications are highly risky in patients with acute porphyria (Table 3). Currently, the only specific treatment for acute attacks is intravenous heme (Panhematin [Recordati Rare Diseases] in the United States and Normosang [Orphan Europe] in Europe). Although hospital pharmacies do not stock Panhematin routinely, the supplier will send it by air express on request. To address questions about its use, the American Porphyria Foundation provides a list of specialists according to geographic area in the United States (www.porphyrifoundation.com/content/Find-an-Expert); the European Porphyria Network provides a similar list for Europe (<http://porphyria.eu/en/content/specialist-porphyrilaboratory-map>).

Panhematin is a powder that is reconstituted immediately before use with either sterile water (provided by the manufacturer) or human serum albumin. The dose is 3 to 4 mg per kilogram of body weight, infused over a period of 30 to 40 minutes, once daily. The first indication of a response is a sharp decrease in the porphobilinogen level in urine or plasma; the decrease occurs on day 3 of treatment (after the second or third infusion). Pain and nausea typically resolve

Table 3. Safety of Medications in Patients with Acute Porphyria.*

Medication	Safety
Anticonvulsants	
Phenytoin	Unsafe
Barbiturates (all types)	Unsafe
Valproic acid	Unsafe
Carbamazepine	Unsafe
Primidone	Unsafe
Clonazepam	Possibly unsafe
Lorazepam	Probably safe
Gabapentin	Probably safe
Magnesium sulfate	Probably safe
Propofol	Probably safe
Ketamine	Possibly unsafe
Bromides	Probably safe
Other medications	
Oral contraceptives	Unsafe
Progestins	Unsafe
Carisoprodol	Unsafe
Spirolactone	Unsafe
Furosemide	Probably safe
Imipramine	Possibly unsafe
Chlorpromazine	Probably safe
Ibuprofen	Probably safe
Opioids	Probably safe
Diphenhydramine	Probably safe
Lithium	Probably safe
Meclizine	Probably safe
Aminoglycoside antibiotics	Probably safe
Penicillins	Probably safe
Sulfa antibiotics	Possibly unsafe
Erythromycin	Possibly unsafe
Fluconazole	Possibly unsafe
Nitrofurantoin	Possibly unsafe
Rifampicin	Possibly unsafe
Warfarin	Probably safe

* Agents that are listed as being unsafe should be considered only if a less risky alternative is not available, the indication is urgent, and the use will be short term. Those that are listed as being possibly unsafe should be used with caution, and those that are listed as being probably safe have been deemed so on the basis of use in patients with acute porphyria. More detailed information is provided at <http://porphyriadrugs.com/>, www.porphyrifoundation.com, and www.drugs-porphyrria.org/index.php.

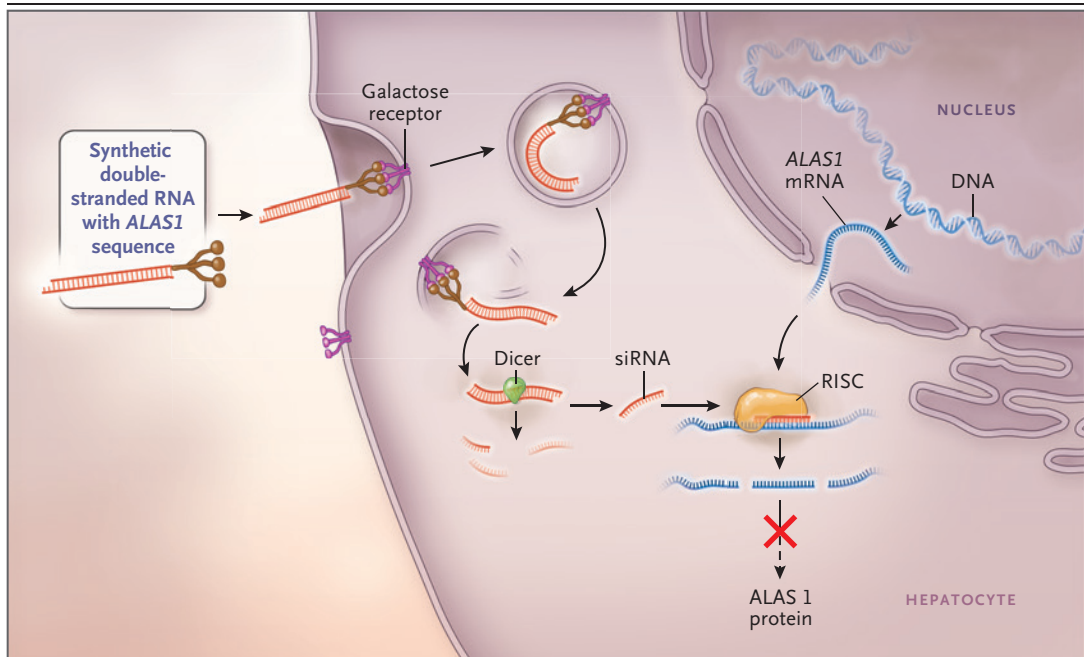


Figure 2. The Mechanism of Small Interfering RNA (siRNA) Therapy.

Synthetic double-stranded RNA containing an *ALAS1*-specific sequence is derivatized with *N*-acetylgalactosamine to target the asialoorosomuroid (galactose) receptor, which is expressed nearly exclusively on hepatocytes. Within the hepatocyte, the RNA is processed into approximately 20-bp fragments by a cellular enzyme (dicer), and then separated into single strands. The strand that is complementary to *ALAS1* (the guide strand) binds to cellular *ALAS1* messenger RNA (mRNA) and enters the RNA-induced silencing complex (RISC), where the new double-stranded RNA is cleaved by a group of factors that include argonaute, a ribonuclease. The result is a reduction in the level of delta ALA synthase 1 protein and decreased production of ALA.

on day 4.²² Motor neuron signs will persist but will not progress. The patient is ready for discharge when narcotics are no longer needed and the oral caloric intake is adequate.

Panhematin is an important, even lifesaving, therapy, but it has shortcomings. In solution, it is unstable and must be infused as soon as it is reconstituted as described in the package insert.²³ It is administered intravenously through a large peripheral vein or a central line. Use of a small vessel may result in painful phlebitis. The risk of phlebitis is reduced by preparation of the solution with human albumin rather than water.²⁴ Panhematin causes platelet aggregation with a sharp decrease in the peripheral count that recovers over a 5-hour period. Prolongation of the prothrombin time is also seen and lasts approximately 24 hours.²⁵ The changes in coagulation values have not been associated with bleeding, but caution is indicated in patients who are already taking an anticoagulant. Finally, frequent

courses of heme can result in hepatic iron buildup and injury due to iron overload.²⁶

Alternatives to the use of intravenous heme are being developed. One approach is the use of gene therapy in which the normal hydroxymethylbilane synthase gene is delivered to hepatocytes in a viral vector (ClinicalTrials.gov number, NCT02082860). Although the results of preclinical studies were encouraging,²⁷ a pilot investigation involving humans with frequent acute attacks showed no effect on levels of delta aminolevulinic acid or porphobilinogen.²⁸ Adverse events related to administration of the vector were not seen.

A second approach involves the use of a small interfering RNA (siRNA) directed against delta aminolevulinic acid synthase 1, with the aim of reducing production of delta aminolevulinic acid (Fig. 2). The siRNA (Givosiran, Alnylam Pharmaceuticals) is derivatized with *N*-acetylgalactosamine for hepatocyte targeting.²⁹ Studies in mice have provided proof of concept.^{30,31} In human

phase 1 studies, after a single subcutaneous injection of the siRNA, expression of delta aminolevulinic acid synthase 1 decreased within 24 hours and remained within the target range for at least 1 month. Side effects as of this writing have been minor (www.alnylam.com/web/assets/SSIEM-2016_AS1_Ph1_Capella_Deck_090716.pdf). Studies involving patients who have acute intermittent porphyria with frequent symptom flares are under way. The siRNA approach, if successful, would be a substantial improvement over intravenous heme because of its ease of administration and sustained effect (NCT02452372).

Frequent spontaneous acute attacks have a highly variable course, lasting from several months to many years, and they are often associated with a markedly impaired quality of life.⁹ Prophylactic heme infusion is helpful in some cases.^{1,2} When attacks are catamenial, ovulatory suppression with a gonadotropin-releasing hormone agonist may be tried.¹³ Oral contraceptives are risky, as already noted. At present, liver transplantation is the only remedy for recurring attacks with a poor response to heme and neurologic progression.³² Pregnancy usually is uneventful. Acute flares that occur during gestation can be treated with intravenous heme without risk to the fetus.³³

Management of acute intermittent porphyria also involves genetic screening of family members, especially the patient's parents, siblings, and children. Family members who are found to carry the mutation are counseled about avoiding an acute attack and the importance of screening the next generation. They can be reassured that most of the risk of an acute attack is associated with manageable environmental factors. Across more than 400 identified mutations, there is little evidence that genotype predicts phenotype.⁸

PROGNOSIS

Before the 1980s, mortality among patients with acute attacks of porphyria was approximately 25%. With early diagnosis and specific treatment, the outlook is much improved.^{34,35}

When motor neuron disease is part of an acute attack, the associated weakness resolves slowly but usually completely over a 1-year period; occasionally, foot drop or wrist drop do not resolve during the recovery period. Studies involving older patients with acute intermittent por-

Table 4. Susceptibility Factors in Patients with Porphyria Cutanea Tarda.*

Factor	Prevalence <i>percent</i>
Acquired factors	
Hepatitis C virus infection	69
Alcohol consumption	87
Tobacco use	81
Estrogen use (in female patients)	66
Human immunodeficiency virus infection	13
Genetic factors	
Uroporphyrinogen decarboxylase mutation	17
Genetic hemochromatosis	53
C282Y/C282Y genotype	6
C282Y/H63D genotype	8
C282Y/- and H63D/- genotypes	39

* Data are from Jalil et al.⁴¹

phyria have shown an increased prevalence of chronic liver disease and kidney disease, possibly owing to long-term toxic effects of delta aminolevulinic acid.^{36,37} The risk of renal damage may be related to genetic variation in peptide transporter 2, which transports delta aminolevulinic acid as well as short peptides.³⁸ Although liver disease seldom reaches the stage of cirrhosis, a Swedish study indicated that the risk of primary liver cancer (mainly hepatocellular carcinoma) is increased by a factor of 80 after the age 50 of years (and by a factor of 150 in women); annual screening with measurement of the alpha-fetoprotein level and abdominal imaging (e.g., ultrasonography) is recommended.³⁹

PORPHYRIA CUTANEA TARDA

Porphyria cutanea tarda, the most prevalent of the porphyrias, is estimated to affect 5 to 10 persons per 100,000 population. It is due to inhibition of uroporphyrinogen decarboxylase, the fifth enzyme in the heme biosynthetic pathway (Fig. 1). Excess hepatic iron plays a large role in the pathogenesis, with more than 50% of patients with porphyria cutanea tarda carrying a mutation for hemochromatosis (Table 4). Mutation of uroporphyrinogen decarboxylase is present in a minority of these patients and is not essential for disease expression.⁴⁰

PATHOBIOLOGY AND MANIFESTATIONS

Photosensitivity in porphyria cutanea tarda is due to excess circulating porphyrins, which transition to an excited state after exposure to blue light (peak wavelength, 410 nm). With relaxation to the previous ground state, they release energy that appears as fluorescence *in vitro* and causes injury to the skin. The onset is usually after the age of 40 years and is characterized by skin friability and chronic, blistering lesions on sun-exposed areas, most often the back of the hands (Table 1). Women may notice the growth of facial hair. The excess uroporphyrin turns the urine brown or reddish brown.

Essentially all patients with clinical disease have at least two of the known susceptibility factors (Table 4), which together reduce uroporphyrinogen decarboxylase activity by approximately 80%.⁴¹ Patients with a uroporphyrinogen decarboxylase mutation in one allele have a 50% loss of activity at baseline but will have symptoms only with inhibition of the residual enzyme by one or more of the exogenous factors (Table 4).⁴² The inhibitory chemical is uroporphomethene, a product of uroporphyrinogen that arises within hepatocytes,⁴³ possibly by a cytochrome P-450–mediated oxidation.^{44,45}

DIAGNOSIS

A urine or plasma porphyrin profile with a predominance of uroporphyrin and heptacarboxyporphyrin is diagnostic of porphyria cutanea tarda, provided that levels of delta aminolevulinic acid and porphobilinogen are normal or only minimally elevated (Table 2). Patients with hereditary coproporphyrin and variegate porphyria may present with similar cutaneous symptoms, but these conditions can be distinguished from porphyria cutanea tarda by measuring levels of fecal coproporphyrin (which are elevated in hereditary coproporphyrin) and plasma porphyrins with a fluorescence emission peak at 626 nm (in variegate porphyria).⁴⁶

Pseudoporphyria is a bullous eruption that resembles porphyria cutanea tarda clinically but with normal levels of plasma and urine porphyrins. It is often idiopathic but sometimes attributable to medications, especially nonsteroidal antiinflammatory drugs.⁴⁷ It does not involve iron excess, but the pathobiology is otherwise unknown.

Finally, late-onset congenital erythropoietic porphyria may mimic porphyria cutanea tarda

with respect to the cutaneous injury and urine porphyrin profile.⁴⁸ The differentiating feature is markedly elevated levels of erythrocyte porphyrins in congenital erythropoietic porphyria.

TREATMENT

Hepatic iron depletion by means of phlebotomy, along with restriction of alcohol, tobacco, and estrogen, produces remission.⁴⁹ Patients who have anemia or who have adverse effects with phlebotomy may take an oral iron chelator. In a pilot study, deferasirox (Exjade) at a dose of 250 to 500 mg per day (an off-label use) appeared to be effective, albeit less efficient than phlebotomy; side effects were minor at this dose.⁵⁰ The initial end point of treatment is a serum ferritin level at the low end of the normal range (approximately 20 ng per milliliter [454 pmol per liter]), which typically is achieved with three to eight phlebotomies. After a lag of 6 to 8 weeks, urine and plasma uroporphyrin levels decrease and skin lesions clear.

An alternative to iron depletion is low-dose hydroxychloroquine (100 mg) or chloroquine (125 mg), twice weekly (both used on an off-label basis).⁵¹ They act within hepatocytes to mobilize porphyrins, which then undergo urinary excretion. They are more convenient and less costly than phlebotomy, and they are comparably effective.⁵² In early studies of antimalarial doses of hydroxychloroquine, acute elevations in levels of aminotransferase were seen. With the currently recommended dose, the risk of liver injury is minimal, although caution is indicated in patients with cirrhosis or renal insufficiency. Monitoring for retinal changes is recommended at baseline and during treatment.⁵³ The medication can be discontinued after the urine uroporphyrin level has been normal for several months. Because these drugs have no effect on hepatic iron stores, phlebotomy is preferred for patients with genetic hemochromatosis.

Two thirds of patients with porphyria cutanea tarda have hepatitis C virus (HCV) infection (Table 4). Case reports have suggested that eradication of the virus leads to resolution of the skin disease.⁵⁴ The current availability of highly effective antiviral agents creates the possibility of treatment for HCV infection as primary therapy for porphyria cutanea tarda, although the available data are not adequate to determine the success rate and durability of this approach.

PROGNOSIS

The disease responds to initial treatment in at least 90% of cases but can recur. Patients with genetic hemochromatosis require periodic phlebotomy to keep the serum ferritin level below 100 ng per milliliter (225 pmol per liter). Patients who consume more than four alcoholic drinks daily or continue smoking may relapse. However, women who require hormone-replacement therapy can continue to receive transdermal estrogen after remission.⁵⁵ In all patients, an annual check of urine or plasma uroporphyrin levels is recommended for early detection of recurrence and for retreatment.

PROTOPORPHYRIA

Protoporphyrin is due to overproduction of protoporphyrin by the bone marrow. There are two forms, each of which is caused by a distinct genetic mutation: ferrochelatase deficiency, which gives rise to “classical” erythropoietic protoporphyria; and delta aminolevulinic acid synthase 2 hyperactivity, termed X-linked protoporphyria (because the gene encoding delta aminolevulinic acid synthase 2 is located on the X chromosome). Circulating protoporphyrin is excreted entirely into bile; thus, the color of the urine is normal.

MANIFESTATIONS

The symptoms of protoporphyria, which usually start in early childhood as toddlers venture outdoors, consist of intense stinging, burning, and itching of sun-exposed skin. The onset after sun exposure varies but may be within 10 minutes. Older children and adults, particularly those with darker skin, may handle being outdoors for an hour or more. Because an infant’s skin shows little more than mild swelling and erythema, the problem may be termed “sun allergy,” and protoporphyria may not be diagnosed until years later. With repeated injury, mild hyperkeratosis and lichenification may develop over the knuckles and around the mouth (Table 1).

INHERITANCE

Once a puzzle, the inheritance of protoporphyria has become clear. Studies in the 1980s showed that in most patients, just one of the two ferrochelatase alleles is mutated. Because clinical expression varies widely, the disease was classified as autosomal dominant with variable pene-

trance.⁵⁶ However, the loss of enzyme activity in symptomatic cases exceeds 50%, which is not consistent with a single-allele mutation. Moreover, in some families the pattern of inheritance is autosomal recessive.

Clarification came with sequencing noncoding ferrochelatase DNA and finding a mutation in the third intron (IVS3-48T→C), which results in faulty splicing of the messenger RNA and a 20 to 40% loss of ferrochelatase activity. When the splice mutation is paired with an inactivating mutation on the opposite allele, the total reduction in enzyme activity (70 to 90%) reaches the threshold for symptoms of protoporphyria. The prevalence of the splice mutation varies from less than 1% among West Africans to approximately 12% among white Europeans and North Americans and 47% among Japanese persons.⁵⁷ Thus, in the West and Japan, the ferrochelatase/IVS3-48T→C genotype accounts for 85 to 90% of cases of protoporphyria. Approximately 5% of cases of protoporphyria involve a mutation in the gene encoding ferrochelatase in both alleles. Most of the remaining 2 to 10% are X-linked protoporphyria.^{58,59} As with other X-linked diseases, male patients with an activating mutation in the gene encoding delta aminolevulinic acid synthase 2 are severely affected; female heterozygotes are variably photosensitive, reflecting X-inactivation of either the normal or mutated allele.⁶⁰

DIAGNOSIS

The screening test for either type of protoporphyria is measurement of total blood porphyrin, which includes both metal-free protoporphyrin and zinc protoporphyrin. Levels that are 5 to 50 times the upper limit of the normal range are diagnostic (Table 2).

Separate determination of zinc protoporphyrin as a fraction of the total is helpful for a preliminary differentiation between erythropoietic protoporphyria and X-linked protoporphyria. In erythropoietic protoporphyria, zinc protoporphyrin constitutes approximately 5% of the total protoporphyrin in blood, whereas in X-linked protoporphyria, it constitutes 20 to 40%. The determination directs attention to the appropriate gene for mutation analysis. Some reference laboratories measure only zinc protoporphyrin but label it, misleadingly, as “free protoporphyrin.”⁶¹ The level of zinc protoporphyrin is elevated in patients with iron deficiency and lead

poisoning.⁶² The test is not useful in screening for protoporphyria.

TREATMENT

Protoporphyrin is lipophilic, moving readily from erythrocytes into plasma and subcutaneous tissue. As in porphyria cutanea tarda, the peak wavelength for light-mediated porphyrin excitation (410 nm) is in the blue, not ultraviolet, range. Because this wavelength passes through window glass, patients are sensitive to indoor sunlight, as well as some types of artificial light. High-intensity lights for surgical or dental procedures may cause tissue injury unless they are equipped with a yellow filter, which absorbs blue wavelengths. Transparent topical sunscreens, which block ultraviolet light only, are ineffective.

Oral beta-carotene (Lumitene) has been touted as a natural quencher of singlet oxygen, which may mediate protoporphyrin-induced injury. The quenching of singlet oxygen by beta-carotene, however, has been shown only *in vitro* and may not occur in intact cells.⁶³ Less than one third of patients with protoporphyria report positive results with this supplement.⁶⁴

Case reports suggest a benefit of other oral medications — activated charcoal and colestipol.^{65,66} In theory, they facilitate protoporphyrin excretion by binding it in the bowel lumen and preventing its enterohepatic recirculation.

Afamelanotide (Scenesse, Clinuvel Pharmaceuticals) is a new therapy based on the observation that sun-related symptoms are inversely related to skin pigmentation in people with protoporphyria. This congener of α -melanocyte-stimulating hormone increases production of eumelanin. It is supplied as a sustained-release subcutaneous implant. Skin darkening starts within a few days after placement of the implant and persists for 3 to 4 weeks. Phase 3, controlled studies showed benefit in patients with protoporphyria,^{67,68} and the medication was approved in Europe. It is under review by the Food and Drug Administration.

Avoidance of sunlight is currently the principal recourse for many patients with protoporphyria. Consequently, approximately 50% of these patients have a vitamin D deficiency.⁶⁹ Half of adult female patients and one third of male patients with this condition also have iron-deficiency anemia, the basis for which is unclear. Hepcidin regulation and intestinal iron absorption appear to be normal.⁷⁰

PROGNOSIS

Protoporphyria severely limits the career choices and social activities of patients,⁶⁴ who are also at risk for liver disease. Excess protoporphyrin from the marrow fluxes through hepatocytes into bile, leaving intracellular crystal deposits. Pigment gallstones are common and often cause symptoms in patients before 30 years of age.⁷¹ In approximately 5% of patients, cholestasis develops, which progresses rapidly to hepatic fibrosis and liver failure.⁷² Male patients with X-linked protoporphyria, in whom porphyrin levels are on average twice those seen in patients with erythropoietic protoporphyria, may be at particular risk for this complication.

Intravenous heme, exchange transfusion, or both have been helpful in a few reported cases,⁷³ but usually liver transplantation is needed, sometimes followed by bone marrow stem-cell transplantation to prevent recurrent cholestatic injury in the graft.²¹ Increasing plasma protoporphyrin and liver enzyme levels may be harbingers of cholestatic injury and should be monitored every 6 months.

CONCLUSIONS

The porphyrias comprise a group of eight diseases, each representing a defect in one of the eight steps of heme formation. The four types discussed here are those most likely to be encountered in clinical practice. They differ strikingly in their respective manifestations and management, reflecting the consequences of impaired function at a specific point in the heme synthetic pathway. Potential new therapies are emerging, and their development is encouraged in part by orphan-disease legislation in the United States and Europe.

Dr. Bissell reports receiving fees for participating in clinical trials from Clinuvel Pharmaceuticals and Alnylam Pharmaceuticals and receiving consulting fees from Recordati Rare Diseases and Mitsubishi Tanabe Pharma; Dr. Anderson, receiving grant support from Clinuvel Pharmaceuticals, Alnylam Pharmaceuticals, and Recordati Rare Diseases; and Dr. Bonkovsky, receiving grant support and consulting fees from Clinuvel Pharmaceuticals, Alnylam Pharmaceuticals, Recordati Rare Diseases, and Mitsubishi Tanabe Pharma. No other potential conflict of interest relevant to this article was reported.

Disclosure forms provided by the authors are available with the full text of this article at NEJM.org.

We thank our colleagues in the Porphyrias Rare Disease Clinical Research Network (U54 DK083909) for helpful discussion and comments.

REFERENCES

- Anderson KE, Bloomer JR, Bonkovsky HL, et al. Recommendations for the diagnosis and treatment of the acute porphyrias. *Ann Intern Med* 2005;142:439-50.
- Whately SD, Badminton MN. Acute intermittent porphyria. In: Pagon RA, Adam MP, Ardinger HH, et al., eds. *GeneReviews*. Seattle: University of Washington, 2013.
- Gross U, Sassa S, Jacob K, et al. 5-Aminolevulinic acid dehydratase deficiency porphyria: a twenty-year clinical and biochemical follow-up. *Clin Chem* 1998;44:1892-6.
- Xu W, Warner CA, Desnick RJ. Congenital erythropoietic porphyria: identification and expression of 10 mutations in the uroporphyrinogen III synthase gene. *J Clin Invest* 1995;95:905-12.
- Nordmann Y, Puy H, Da Silva V, et al. Acute intermittent porphyria: prevalence of mutations in the porphobilinogen deaminase gene in blood donors in France. *J Intern Med* 1997;242:213-7.
- Chen B, Solis-Villa C, Hakenberg J, et al. Acute intermittent porphyria: predicted pathogenicity of HMBS variants indicates extremely low penetrance of the autosomal dominant disease. *Hum Mutat* 2016;37:1215-22.
- Elder G, Harper P, Badminton M, Sandberg S, Deybach JC. The incidence of inherited porphyrias in Europe. *J Inher Metab Dis* 2013;36:849-57.
- Andersson C, Floderus Y, Wikberg A, Lithner F. The W198X and R173W mutations in the porphobilinogen deaminase gene in acute intermittent porphyria have higher clinical penetrance than R167W: a population-based study. *Scand J Clin Lab Invest* 2000;60:643-8.
- Naik H, Stoecker M, Sanderson SC, Balwani M, Desnick RJ. Experiences and concerns of patients with recurrent attacks of acute hepatic porphyria: a qualitative study. *Mol Genet Metab* 2016;119:278-83.
- Liu YP, Lien WC, Fang CC, Lai TI, Chen WJ, Wang HP. ED presentation of acute porphyria. *Am J Emerg Med* 2005;23:164-7.
- Usalan C, Erdem Y, Altun B, et al. Severe hyponatremia due to SIADH provoked by acute intermittent porphyria. *Clin Nephrol* 1996;45:418.
- Magnussen CR, Doherty JM, Hess RA, Tschudy DP. Grand mal seizures and acute intermittent porphyria: the problem of differential diagnosis and treatment. *Neurology* 1975;25:121-5.
- Innala E, Bäckström T, Bixo M, Andersson C. Evaluation of gonadotropin-releasing hormone agonist treatment for prevention of menstrual-related attacks in acute porphyria. *Acta Obstet Gynecol Scand* 2010;89:95-100.
- Case Records of the Massachusetts General Hospital (Case 20-2008). *N Engl J Med* 2008;358:2813-25.
- Bonkovsky HL, Maddukuri VC, Yazici C, et al. Acute porphyrias in the USA: features of 108 subjects from porphyrias consortium. *Am J Med* 2014;127:1233-41.
- Matern SE, Tefferi A. Acute porphyria: the cost of suspicion. *Am J Med* 1999;107:621-3.
- Brennan MJ, Cantrill RC. Delta-aminolaevulinic acid is a potent agonist for GABA autoreceptors. *Nature* 1979;280:514-5.
- Meyer UA, Schuurmans MM, Lindberg RL. Acute porphyrias: pathogenesis of neurological manifestations. *Semin Liver Dis* 1998;18:43-52.
- Emanuelli T, Pagel FW, Alves LB, Regner A, Souza DO. 5-Aminolevulinic acid inhibits [3H]muscimol binding to human and rat brain synaptic membranes. *Neurochem Res* 2001;26:101-5.
- Bissell DM, Lai JC, Meister RK, Blanc PD. Role of delta-aminolevulinic acid in the symptoms of acute porphyria. *Am J Med* 2015;128:313-7.
- Singal AK, Parker C, Bowden C, Thapar M, Liu L, McGuire BM. Liver transplantation in the management of porphyria. *Hepatology* 2014;60:1082-9.
- Bissell DM. Treatment of acute hepatic porphyria with hematin. *J Hepatol* 1988;6:1-7.
- Goetsch CA, Bissell DM. Instability of hematin used in the treatment of acute hepatic porphyria. *N Engl J Med* 1986;315:235-8.
- Anderson KE, Bonkovsky HL, Bloomer JR, Shedlofsky SI. Reconstitution of hematin for intravenous infusion. *Ann Intern Med* 2006;144:537-8.
- Glueck R, Green D, Cohen I, Ts'ao CH. Hematin: unique effects of hemostasis. *Blood* 1983;61:243-9.
- Willandt B, Langendonk JG, Biermann K, et al. Liver fibrosis associated with iron accumulation due to long-term heme-arginate treatment in acute intermittent porphyria: a case series. *JIMD Rep* 2016;25:77-81.
- Yasuda M, Bishop DF, Fowkes M, Cheng SH, Gan L, Desnick RJ. AAV8-mediated gene therapy prevents induced biochemical attacks of acute intermittent porphyria and improves neuromotor function. *Mol Ther* 2010;18:17-22.
- D'Avola D, López-Franco E, Sangro B, et al. Phase I open label liver-directed gene therapy clinical trial for acute intermittent porphyria. *J Hepatol* 2016;65:776-83.
- Biessen EA, Vietsch H, Rump ET, et al. Targeted delivery of oligodeoxynucleotides to parenchymal liver cells in vivo. *Biochem J* 1999;340:783-92.
- Yasuda M, Gan L, Chen B, et al. RNAi-mediated silencing of hepatic Alas1 effectively prevents and treats the induced acute attacks in acute intermittent porphyria mice. *Proc Natl Acad Sci U S A* 2014;111:7777-82.
- Chan A, Liebow A, Yasuda M, et al. Preclinical development of a subcutaneous ALAS1 RNAi therapeutic for treatment of hepatic porphyrias using circulating RNA quantification. *Mol Ther Nucleic Acids* 2015;4:e263.
- Dowman JK, Gunson BK, Mirza DF, Bramhall SR, Badminton MN, Newsome PN. Liver transplantation for acute intermittent porphyria is complicated by a high rate of hepatic artery thrombosis. *Liver Transpl* 2012;18:195-200.
- Marsden JT, Rees DC. A retrospective analysis of outcome of pregnancy in patients with acute porphyria. *J Inher Metab Dis* 2010;33:591-6.
- Jeans JB, Savik K, Gross CR, et al. Mortality in patients with acute intermittent porphyria requiring hospitalization: a United States case series. *Am J Med Genet* 1996;65:269-73.
- Kauppinen R, Mustajoki P. Prognosis of acute porphyria: occurrence of acute attacks, precipitating factors, and associated diseases. *Medicine (Baltimore)* 1992;71:1-13.
- Marsden JT, Chowdhury P, Wang J, et al. Acute intermittent porphyria and chronic renal failure. *Clin Nephrol* 2008;69:339-46.
- Pallet N, Mami I, Schmitt C, et al. High prevalence of and potential mechanisms for chronic kidney disease in patients with acute intermittent porphyria. *Kidney Int* 2015;88:386-95.
- Tchernitchko D, Tavernier Q, Lamoril J, et al. A variant of peptide transporter 2 predicts the severity of porphyria-associated kidney disease. *J Am Soc Nephrol* 2017;28:1924-32.
- Sardh E, Wahlin S, Björnstedt M, Harper P, Andersson DE. High risk of primary liver cancer in a cohort of 179 patients with acute hepatic porphyria. *J Inher Metab Dis* 2013;36:1063-71.
- Liu LU, Phillips J, Bonkovsky H. Familial porphyria cutanea tarda. In: Pagon RA, Adam MP, Ardinger HH, et al., eds. *GeneReviews*. Seattle: University of Washington, 2016.
- Jalil S, Grady JJ, Lee C, Anderson KE. Associations among behavior-related susceptibility factors in porphyria cutanea tarda. *Clin Gastroenterol Hepatol* 2010;8:297-302.
- Bonkovsky HL, Poh-Fitzpatrick M, Pimstone N, et al. Porphyria cutanea tarda, hepatitis C, and HFE gene mutations in North America. *Hepatology* 1998;27:1661-9.
- Phillips JD, Bergonia HA, Reilly CA, Franklin MR, Kushner JP. A porphomethene inhibitor of uroporphyrinogen decarboxylase causes porphyria cutanea tarda. *Proc Natl Acad Sci U S A* 2007;104:5079-84.
- Sinclair PR, Gorman N, Walton HS, et al. CYP1A2 is essential in murine uroporphyrin caused by hexachlorobenzene and

- iron. *Toxicol Appl Pharmacol* 2000;162:60-7.
45. Wickliffe JK, Abdel-Rahman SZ, Lee C, et al. CYP1A2*1F and GSTM1 alleles are associated with susceptibility to porphyria cutanea tarda. *Mol Med* 2011;17:241-7.
 46. Poh-Fitzpatrick MB. A plasma porphyrin fluorescence marker for variegate porphyria. *Arch Dermatol* 1980;116:543-7.
 47. LaDuca JR, Bouman PH, Gaspari AA. Nonsteroidal antiinflammatory drug-induced pseudoporphyria: a case series. *J Cutan Med Surg* 2002;6:320-6.
 48. Berry AA, Desnick RJ, Astrin KH, Shabbeer J, Lucky AW, Lim HW. Two brothers with mild congenital erythropoietic porphyria due to a novel genotype. *Arch Dermatol* 2005;141:1575-9.
 49. Ippen H. Treatment of porphyria cutanea tarda by phlebotomy. *Semin Hematol* 1977;14:253-9.
 50. Pandya AG, Nezafati KA, Ashe-Randolph M, Yalamanchili R. Deferasirox for porphyria cutanea tarda: a pilot study. *Arch Dermatol* 2012;148:898-901.
 51. Ashton RE, Hawk JL, Magnus IA. Low-dose oral chloroquine in the treatment of porphyria cutanea tarda. *Br J Dermatol* 1984;111:609-13.
 52. Singal AK, Kormos-Hallberg C, Lee C, et al. Low-dose hydroxychloroquine is as effective as phlebotomy in treatment of patients with porphyria cutanea tarda. *Clin Gastroenterol Hepatol* 2012;10:1402-9.
 53. Marmor MF, Kellner U, Lai TY, Lyons JS, Mieler WF. Revised recommendations on screening for chloroquine and hydroxychloroquine retinopathy. *Ophthalmology* 2011;118:415-22.
 54. Sheikh MY, Wright RA, Burruss JB. Dramatic resolution of skin lesions associated with porphyria cutanea tarda after interferon-alpha therapy in a case of chronic hepatitis C. *Dig Dis Sci* 1998;43:529-33.
 55. Bulaj ZJ, Franklin MR, Phillips JD, et al. Transdermal estrogen replacement therapy in postmenopausal women previously treated for porphyria cutanea tarda. *J Lab Clin Med* 2000;136:482-8.
 56. Went LN, Klasen EC. Genetic aspects of erythropoietic protoporphyria. *Ann Hum Genet* 1984;48:105-17.
 57. Nakano H, Nakano A, Toyomaki Y, et al. Novel ferrochelatase mutations in Japanese patients with erythropoietic protoporphyria: high frequency of the splice site modulator IVS3-48C polymorphism in the Japanese population. *J Invest Dermatol* 2006;126:2717-9.
 58. Whatley SD, Ducamp S, Gouya L, et al. C-terminal deletions in the ALAS2 gene lead to gain of function and cause X-linked dominant protoporphyria without anemia or iron overload. *Am J Hum Genet* 2008;83:408-14.
 59. Balwani M, Doheny D, Bishop DE, et al. Loss-of-function ferrochelatase and gain-of-function erythroid-specific 5-aminolevulinic synthase mutations causing erythropoietic protoporphyria and X-linked protoporphyria in North American patients reveal novel mutations and a high prevalence of X-linked protoporphyria. *Mol Med* 2013;19:26-35.
 60. Brancaloni V, Balwani M, Granata F, et al. X-chromosomal inactivation directly influences the phenotypic manifestation of X-linked protoporphyria. *Clin Genet* 2016;89:20-6.
 61. Gou EW, Balwani M, Bissell DM, et al. Pitfalls in erythrocyte protoporphyrin measurement for diagnosis and monitoring of protoporphyrias. *Clin Chem* 2015;61:1453-6.
 62. Labbé RF, Vreman HJ, Stevenson DK. Zinc protoporphyria: a metabolite with a mission. *Clin Chem* 1999;45:2060-72.
 63. Bosio GN, Breitenbach T, Parisi J, et al. Antioxidant β -carotene does not quench singlet oxygen in mammalian cells. *J Am Chem Soc* 2013;135:272-9.
 64. Holme SA, Anstey AV, Finlay AY, Elder GH, Badminton MN. Erythropoietic protoporphyria in the U.K.: clinical features and effect on quality of life. *Br J Dermatol* 2006;155:574-81.
 65. Gorchein A, Foster GR. Liver failure in protoporphyria: long-term treatment with oral charcoal. *Hepatology* 1999;29:995-6.
 66. Tishler PV, Rosner B. Treatment of erythropoietic protoporphyria with the oral sorbent colestipol: a proof-of-concept clinical trial. *J Am Acad Dermatol* 2014;70:391-2.
 67. Langendonk JG, Balwani M, Anderson KE, et al. Afamelanotide for erythropoietic protoporphyria. *N Engl J Med* 2015;373:48-59.
 68. Biolcati G, Marchesini E, Sorge F, Barbieri L, Schneider-Yin X, Minder EI. Long-term observational study of afamelanotide in 115 patients with erythropoietic protoporphyria. *Br J Dermatol* 2015;172:1601-12.
 69. Spelt JM, de Rooij FW, Wilson JH, Zandbergen AA. Vitamin D deficiency in patients with erythropoietic protoporphyria. *J Inher Metab Dis* 2010;33:Suppl 3:S1-S4.
 70. Bossi K, Lee J, Schmeltzer P, et al. Homeostasis of iron and hepcidin in erythropoietic protoporphyria. *Eur J Clin Invest* 2015;45:1032-41.
 71. Cox TM, Alexander GJ, Sarkany RP. Protoporphyria. *Semin Liver Dis* 1998;18:85-93.
 72. McGuire BM, Bonkovsky HL, Carithers RL Jr, et al. Liver transplantation for erythropoietic protoporphyria liver disease. *Liver Transpl* 2005;11:1590-6.
 73. Reichheld JH, Katz E, Banner BF, Szymanski IO, Saltzman JR, Bonkovsky HL. The value of intravenous heme-albumin and plasmapheresis in reducing postoperative complications of orthotopic liver transplantation for erythropoietic protoporphyria. *Transplantation* 1999;67:922-8.

Copyright © 2017 Massachusetts Medical Society.

IMAGES IN CLINICAL MEDICINE

The *Journal* welcomes consideration of new submissions for Images in Clinical Medicine. Instructions for authors and procedures for submissions can be found on the *Journal's* website at NEJM.org. At the discretion of the editor, images that are accepted for publication may appear in the print version of the *Journal*, the electronic version, or both.